

الحمد لله رب العالمين



Overview of Ophthalmic Evaluation

- Sahba Fekri, MD
- Assistant Professor of Ophthalmology
- Shahid Beheshti University of Medical Sciences



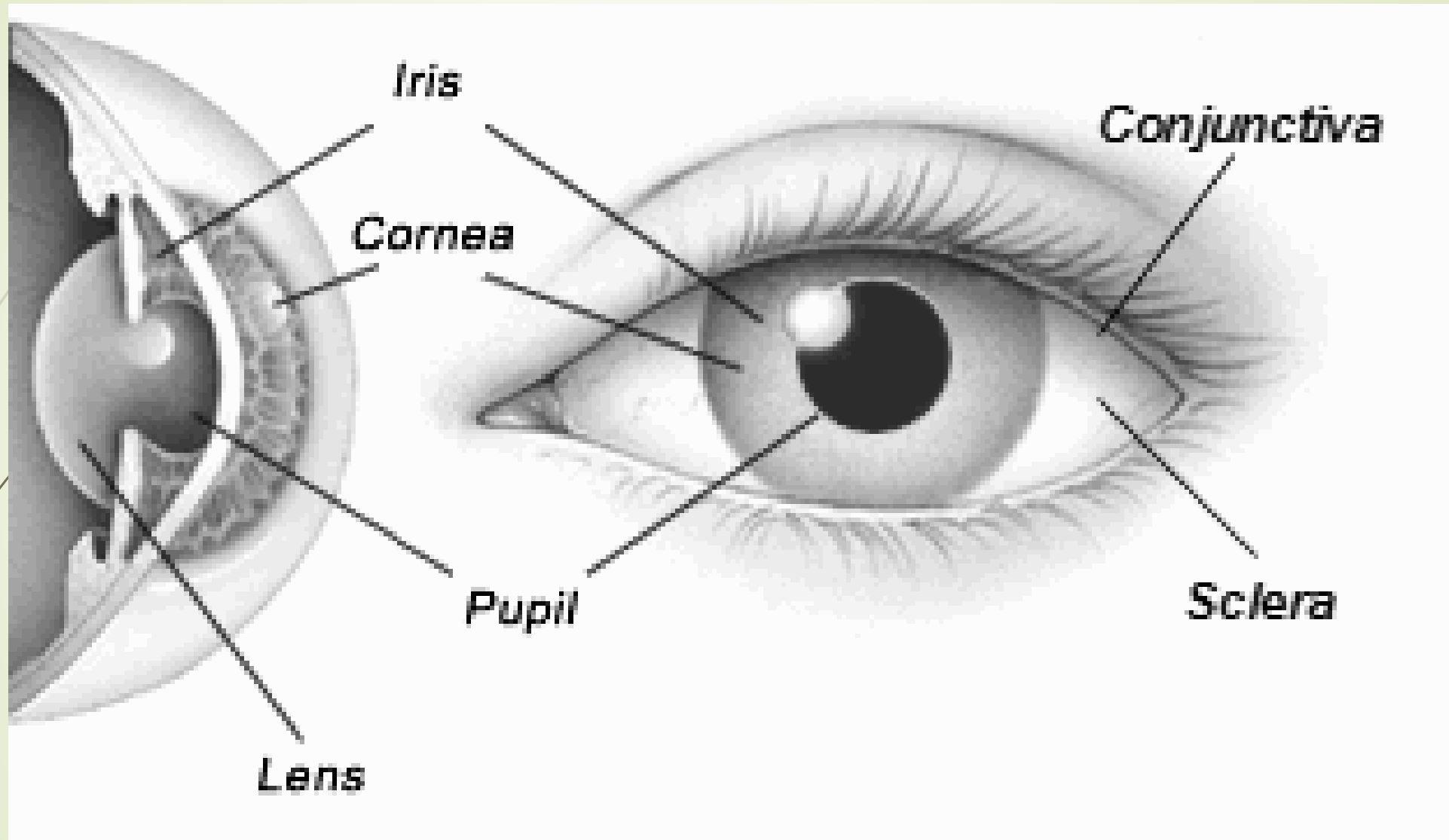
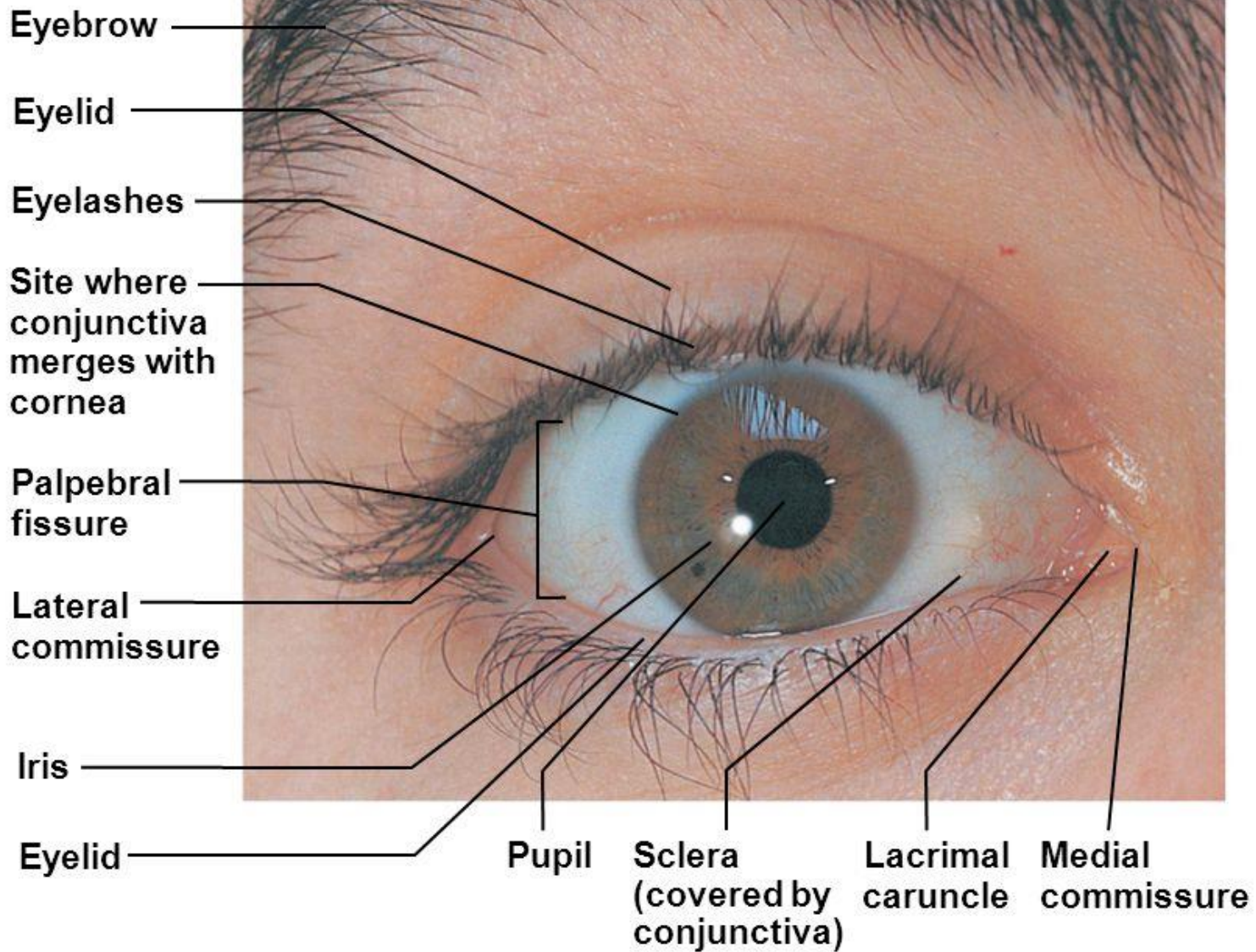
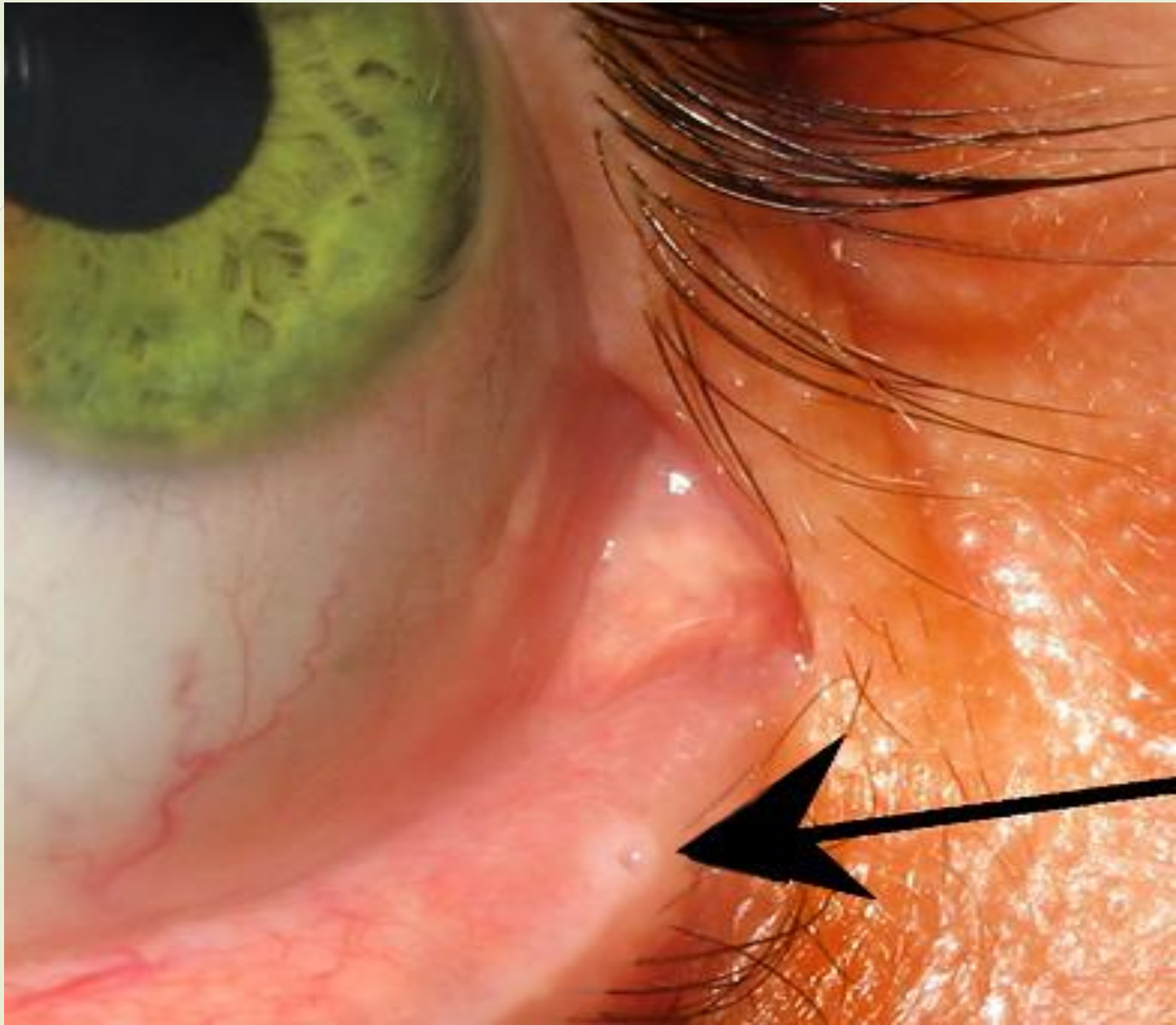
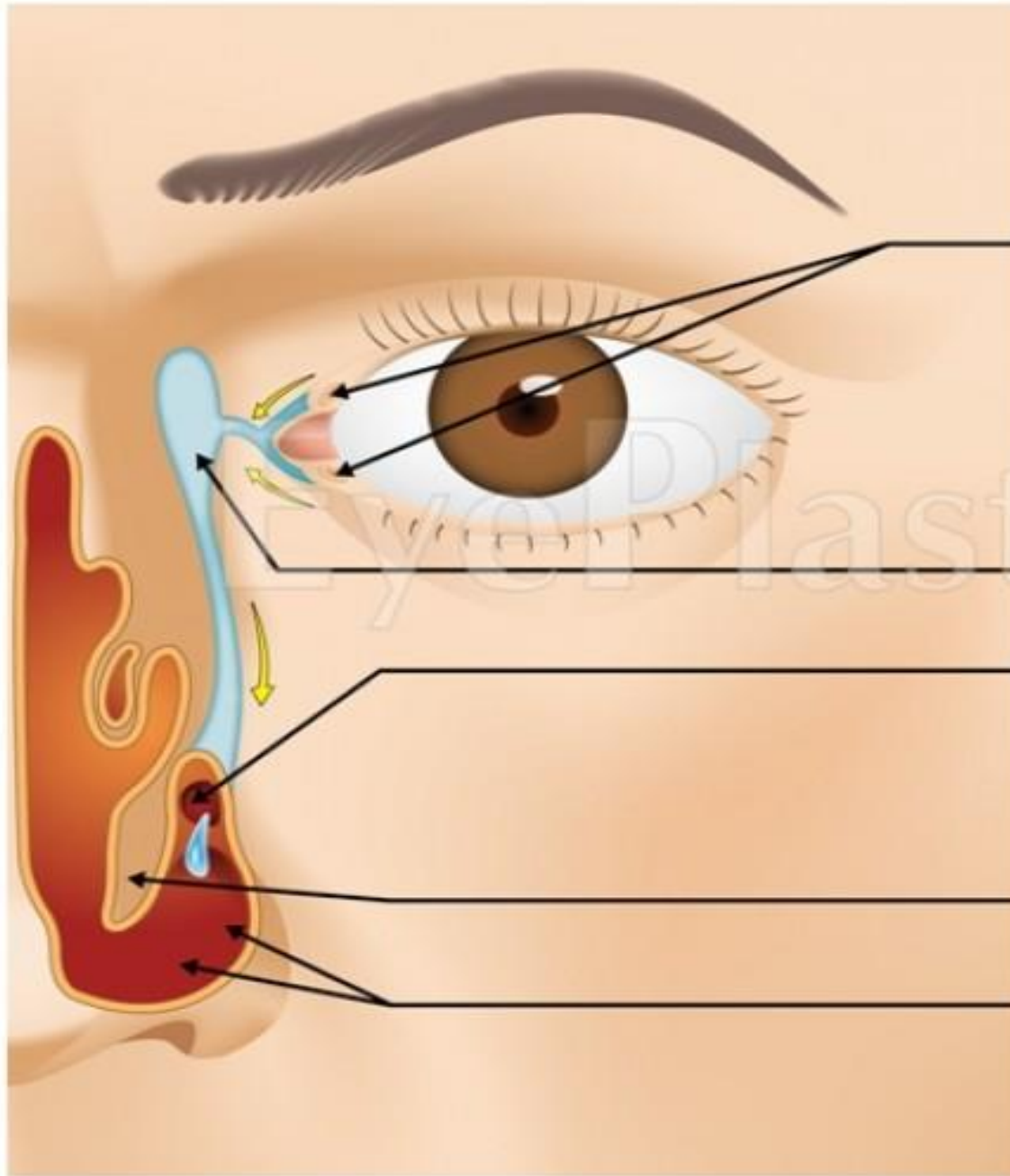


Figure 15.1a The eye and accessory structures.



(a) Surface anatomy of the right eye





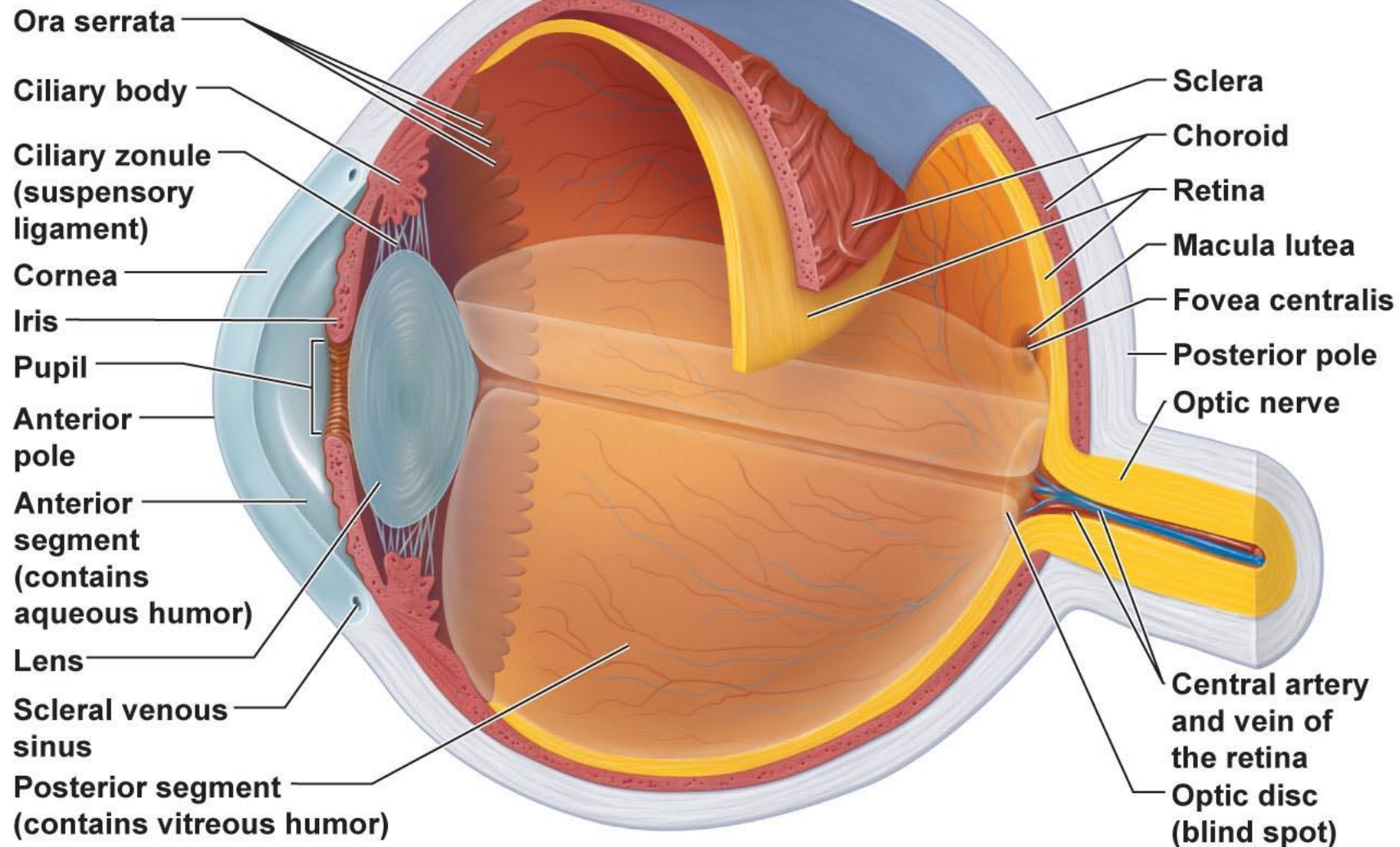
Lacrimate
puncta
(upper
and lower)

Lacrimal sac

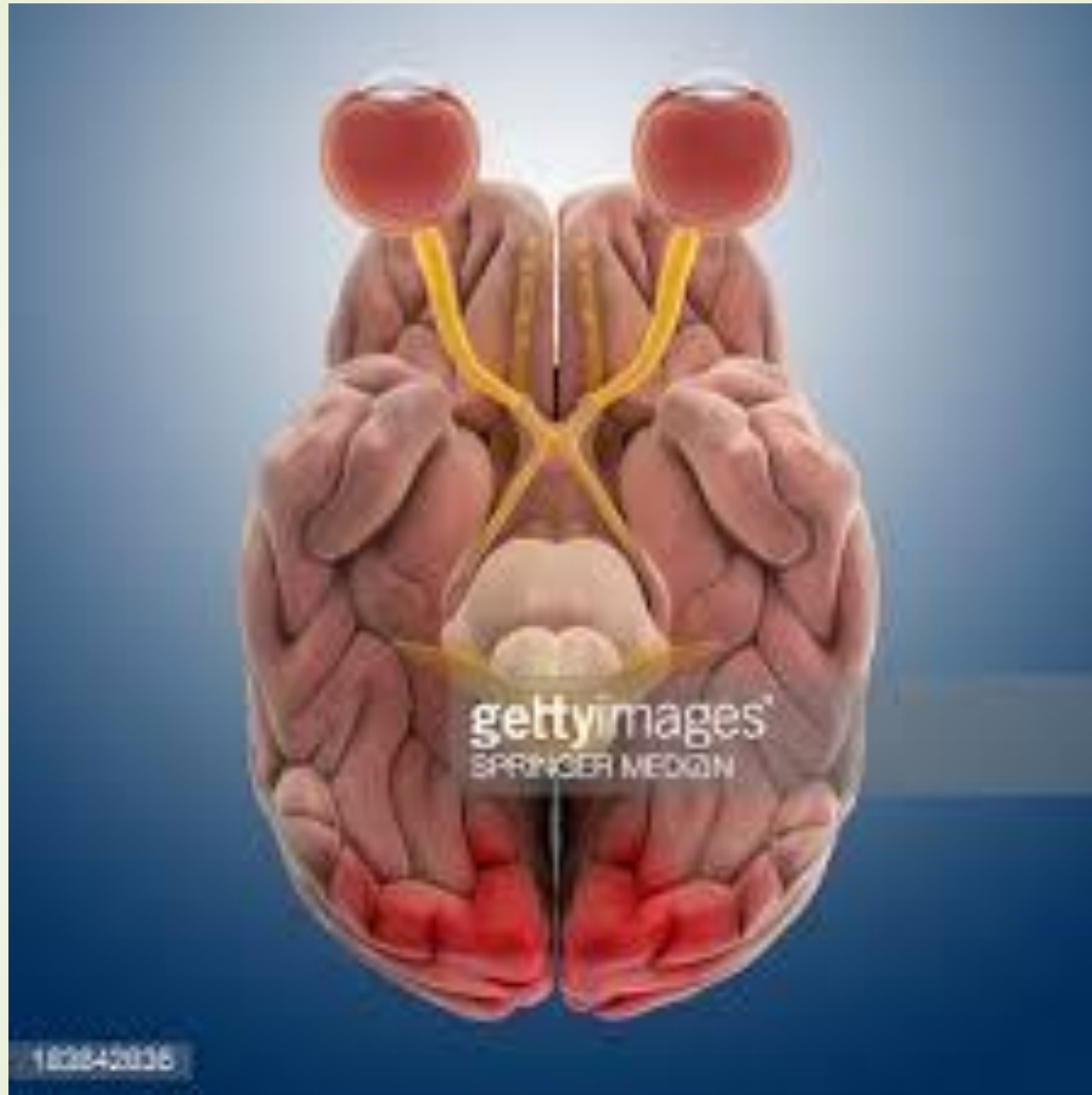
Valve of Hasner


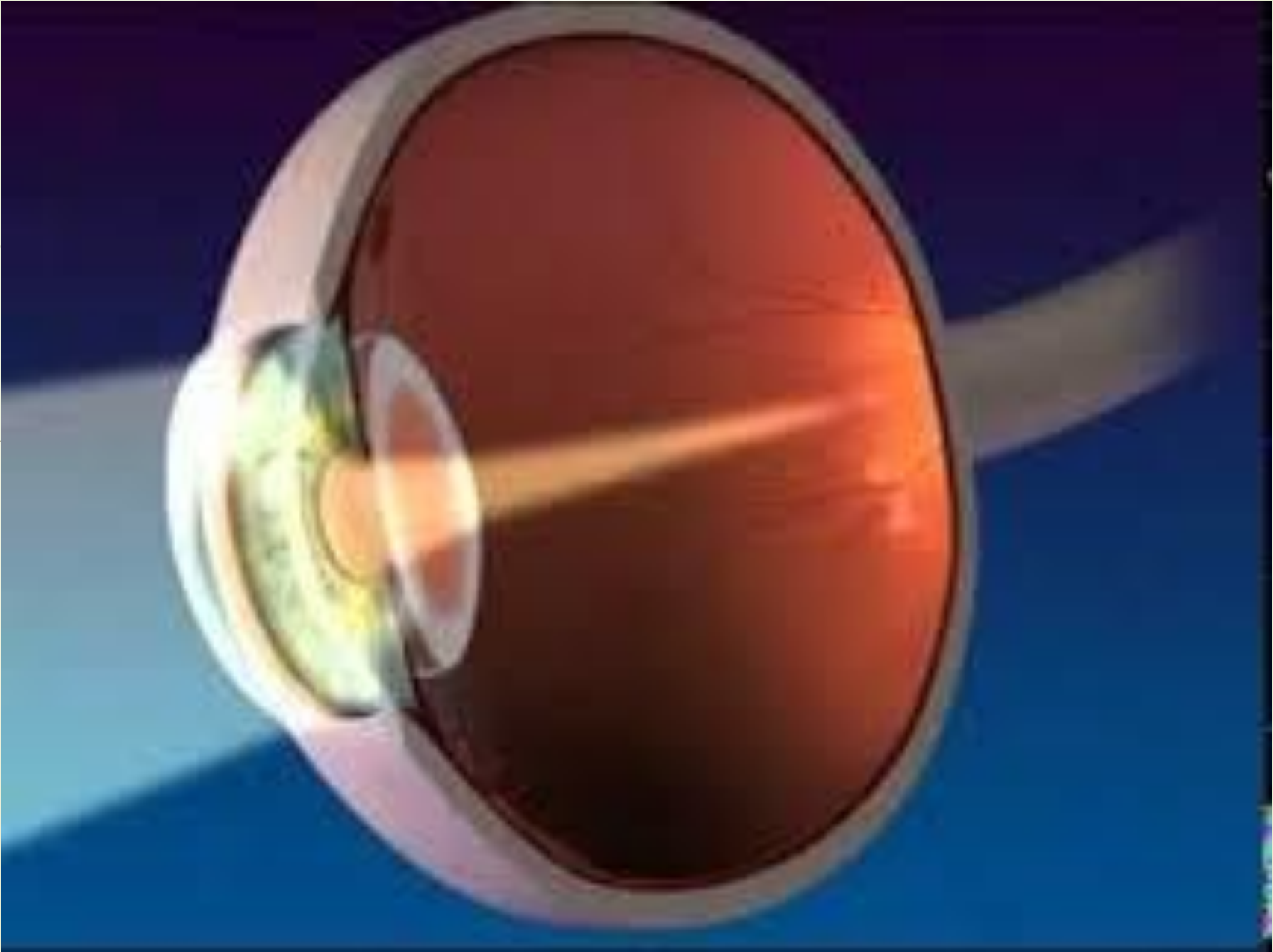
Inferior concha

Mucosa of nasal
cavity

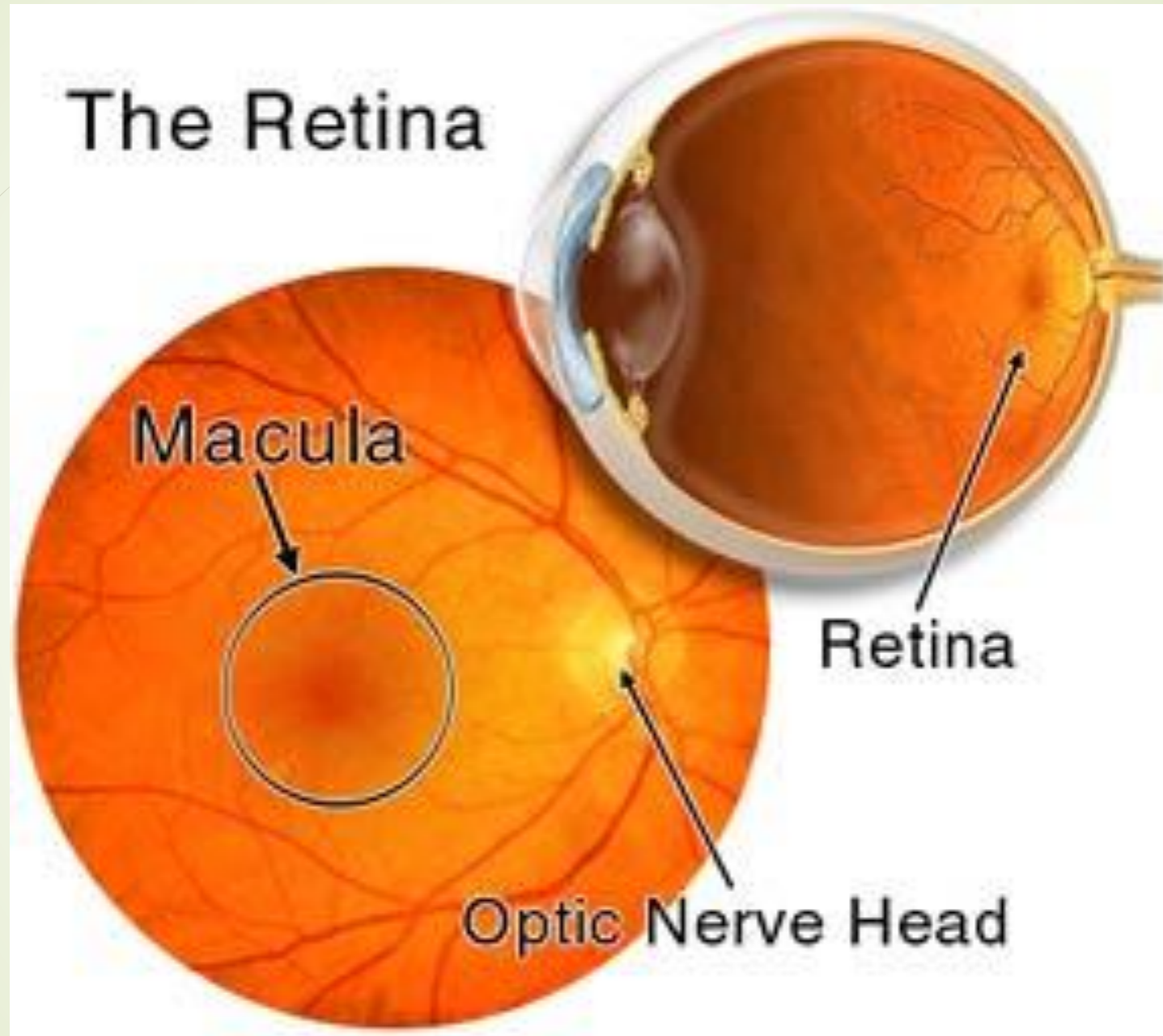


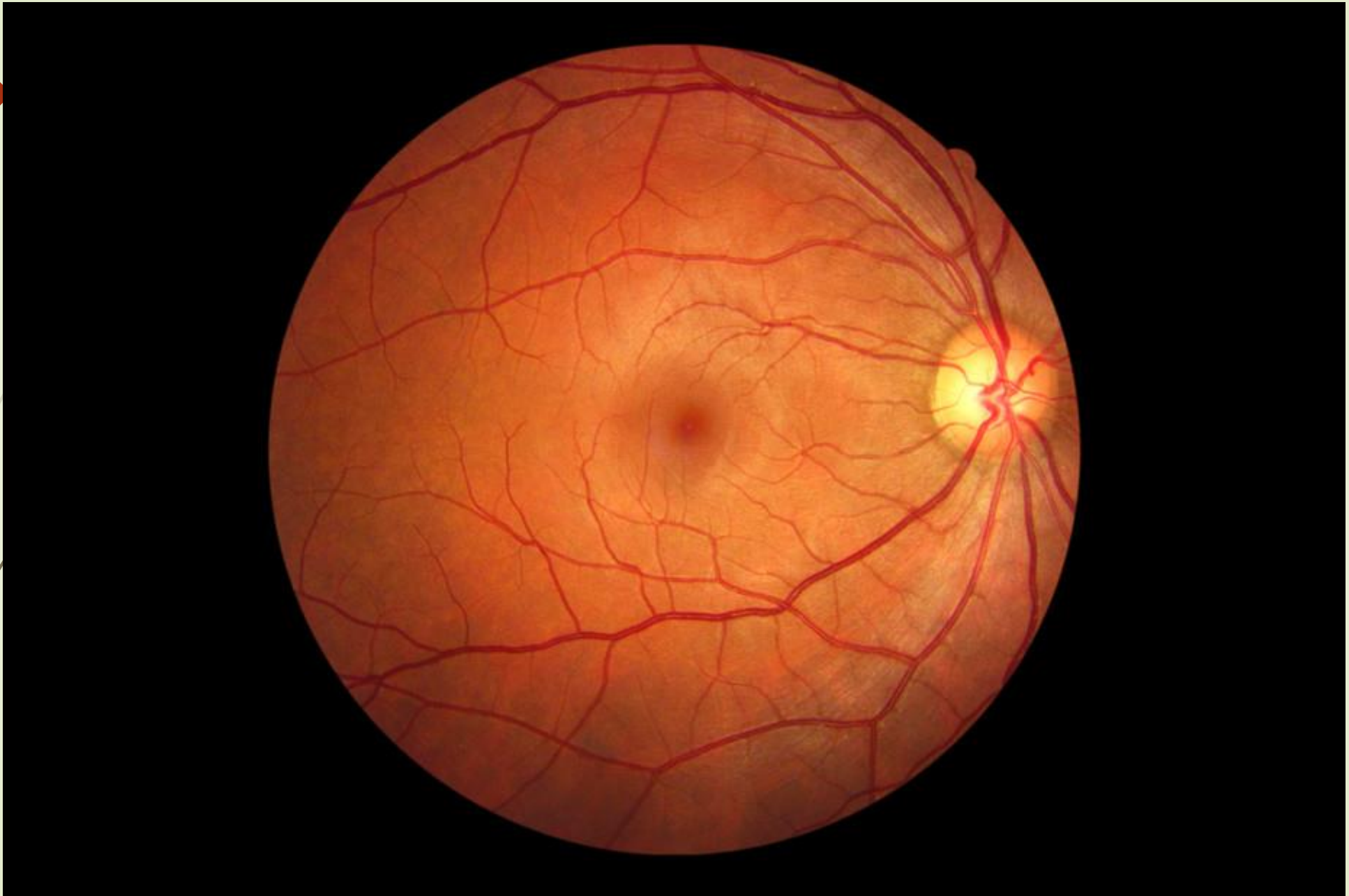
(a) Diagrammatic view. The vitreous humor is illustrated only in the bottom part of the eyeball.



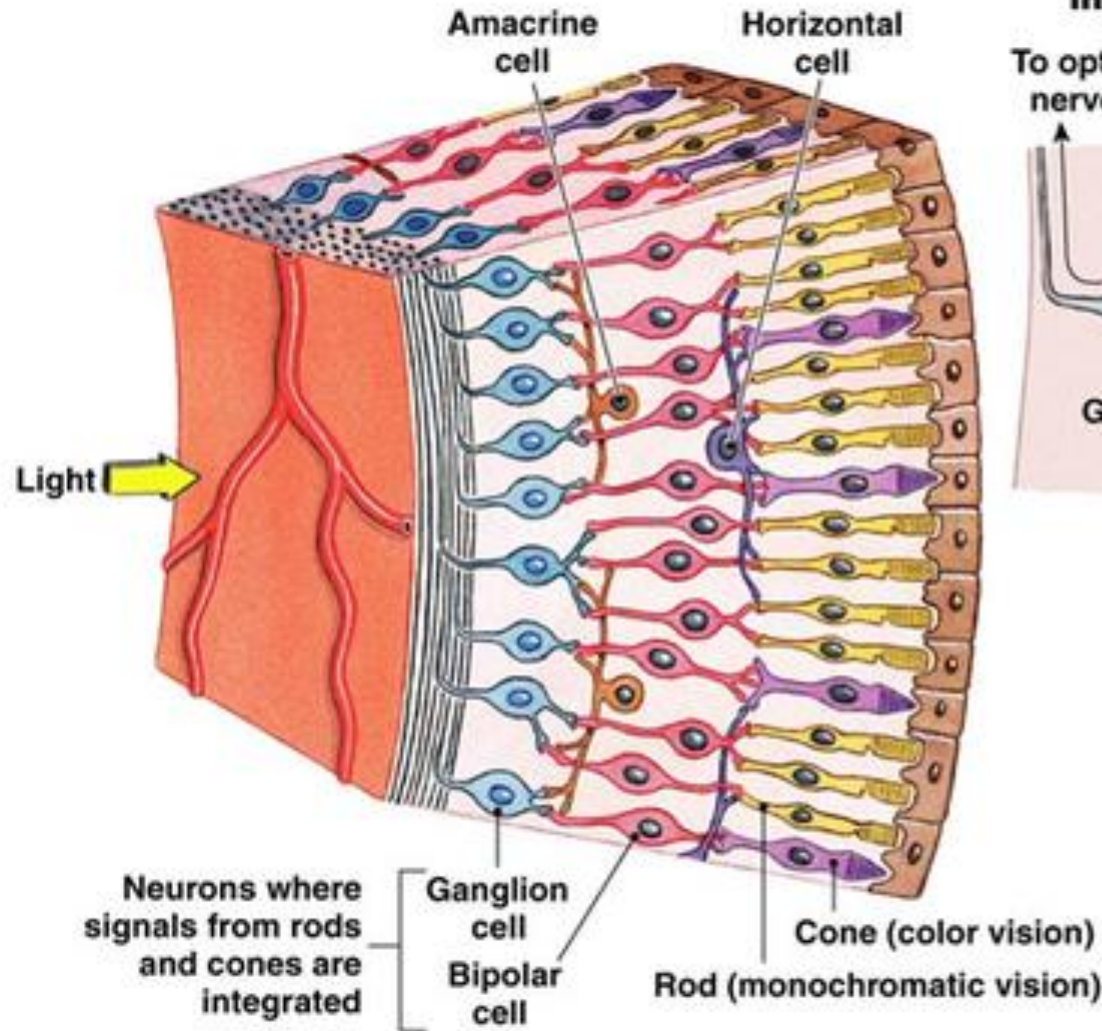


The Retina

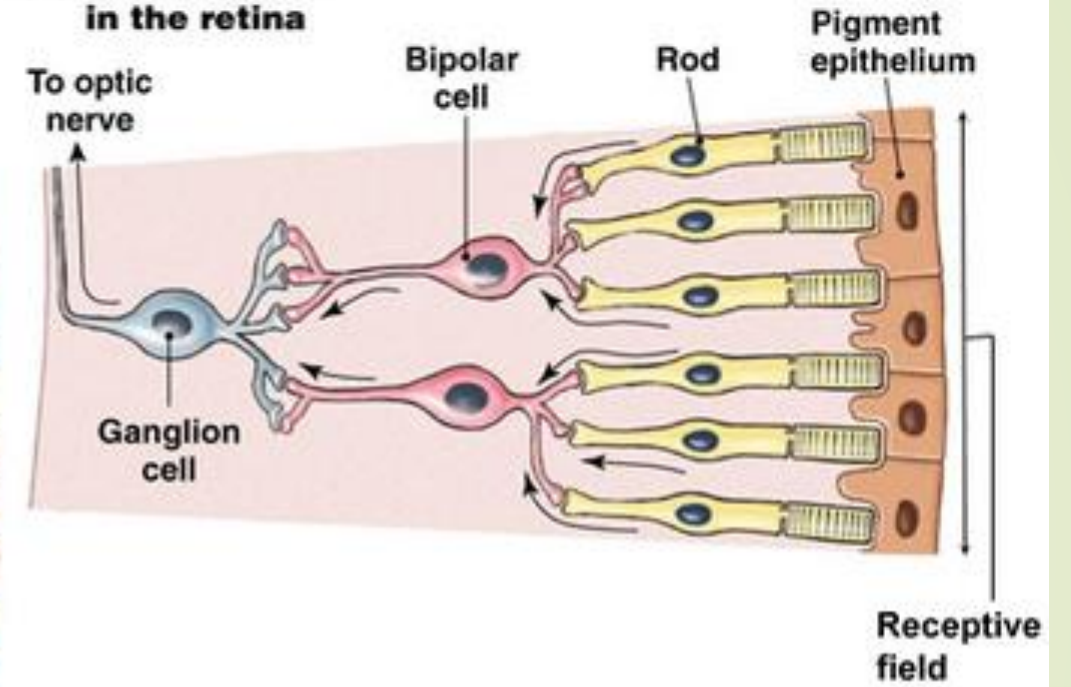


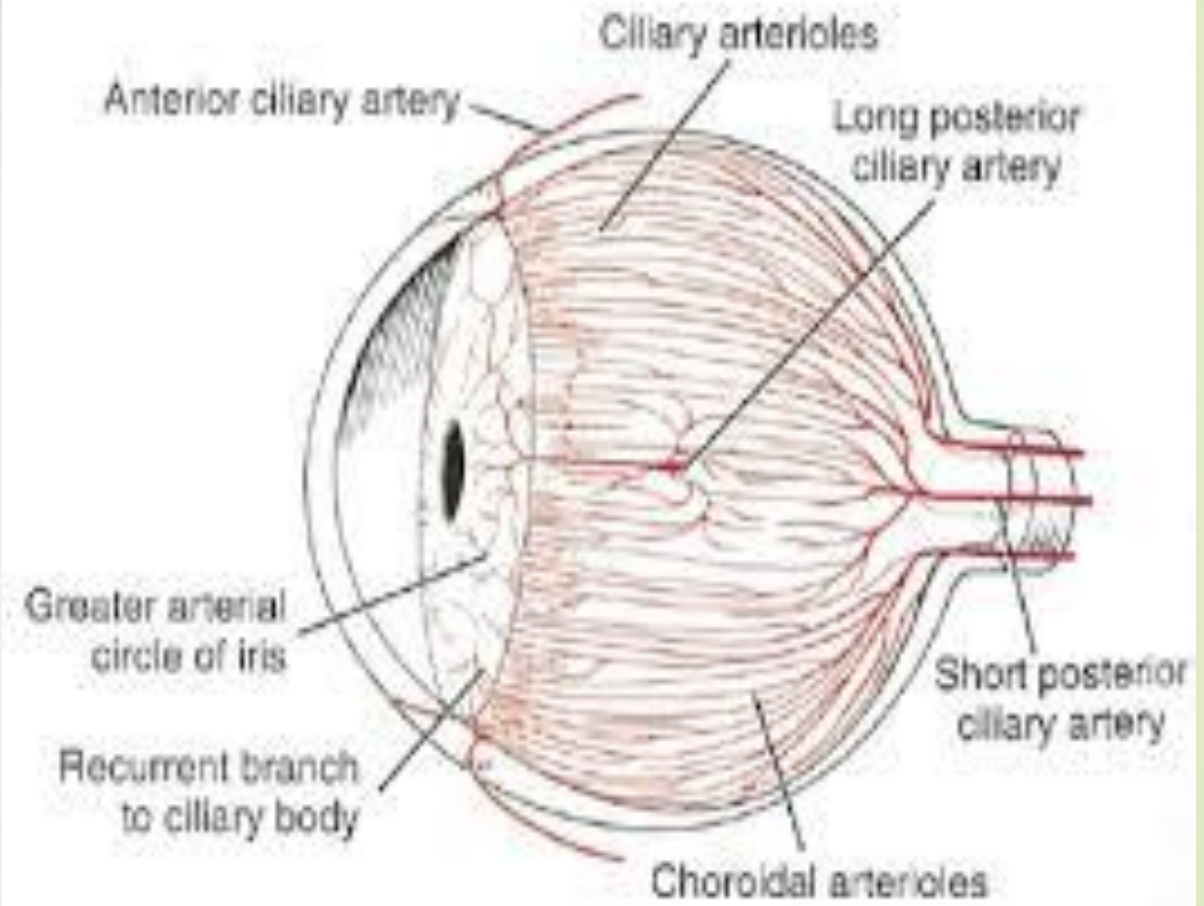
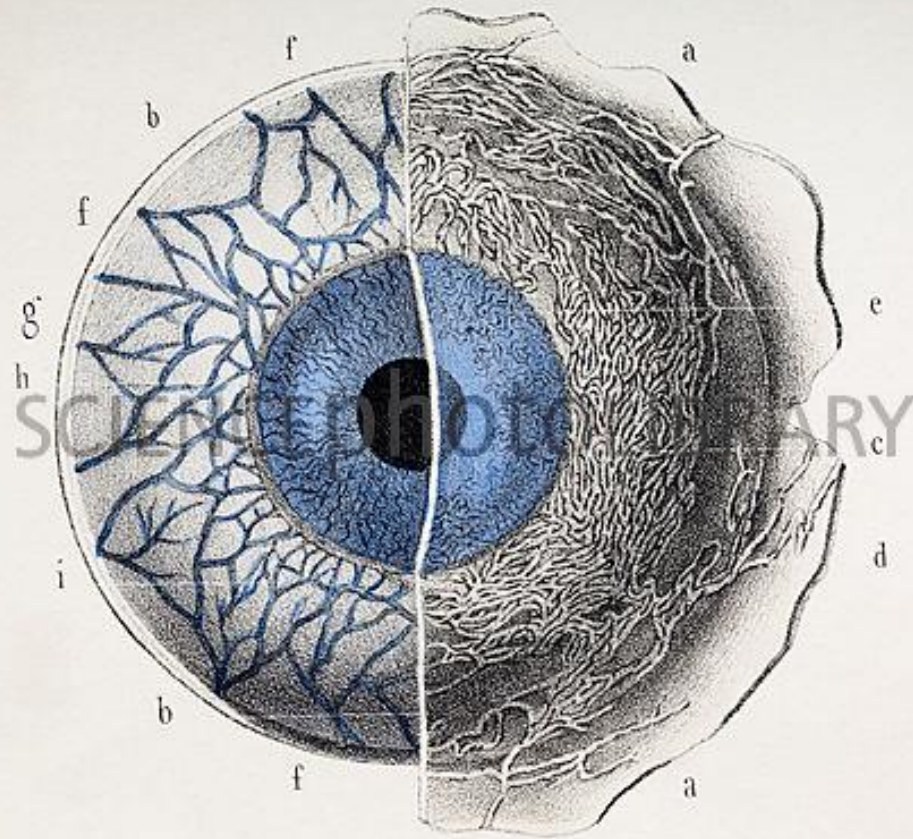


(d) Organization of the retina



(e) Convergence in the retina







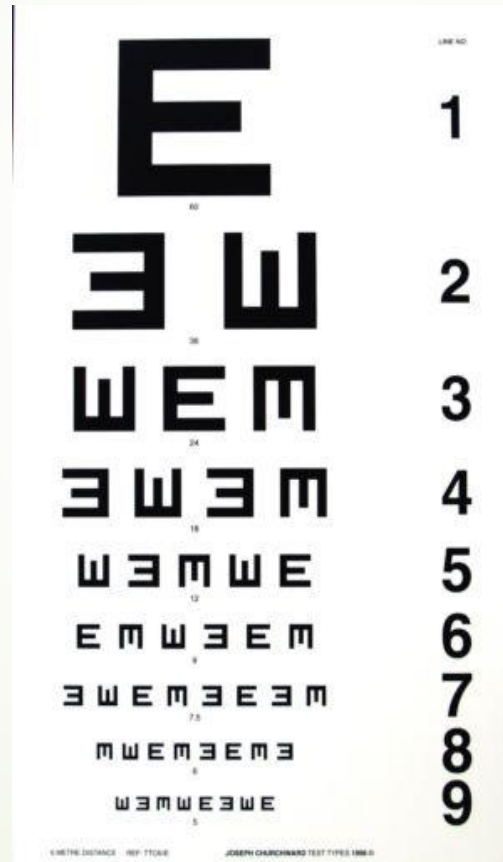
History taking

- ▶ Chief complaint
- ▶ History of present illness
- ▶ Past ocular history
- ▶ Ocular medications
- ▶ General medical & surgical history
- ▶ Systemic medication
- ▶ Allergies
- ▶ Social history
- ▶ Family history
- ▶ Review of systems

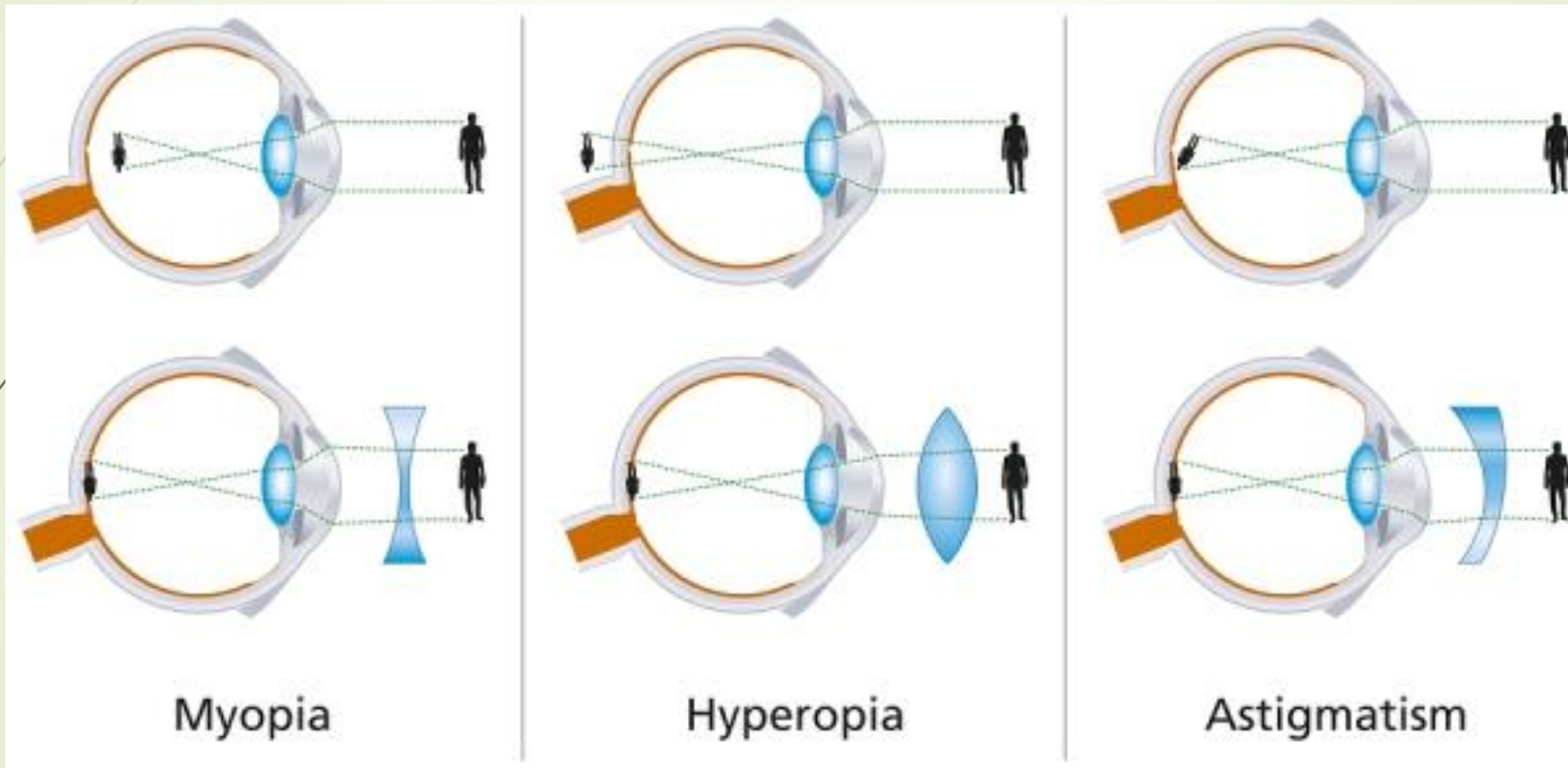



Ophthalmic Examinations

Visual Acuity Examination

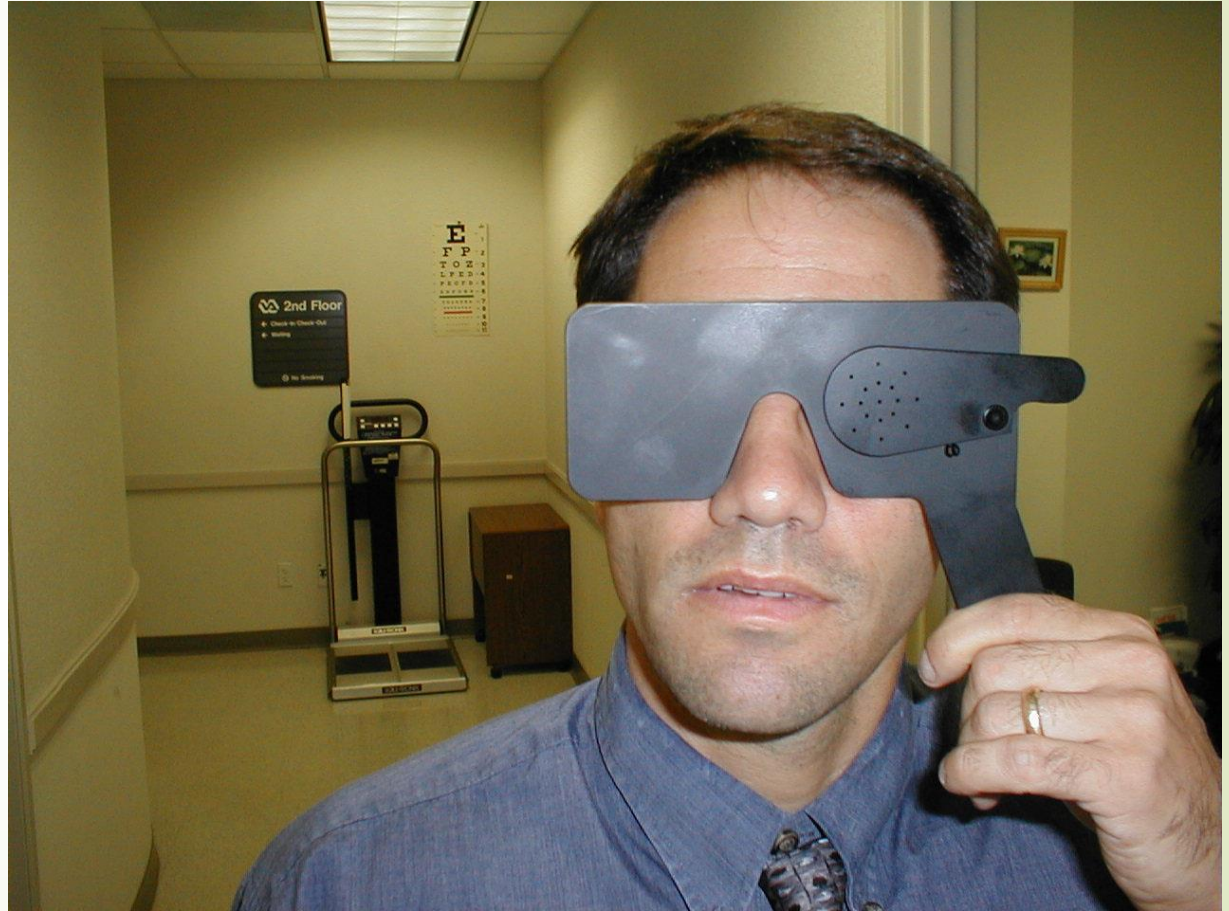

Refractive Errors





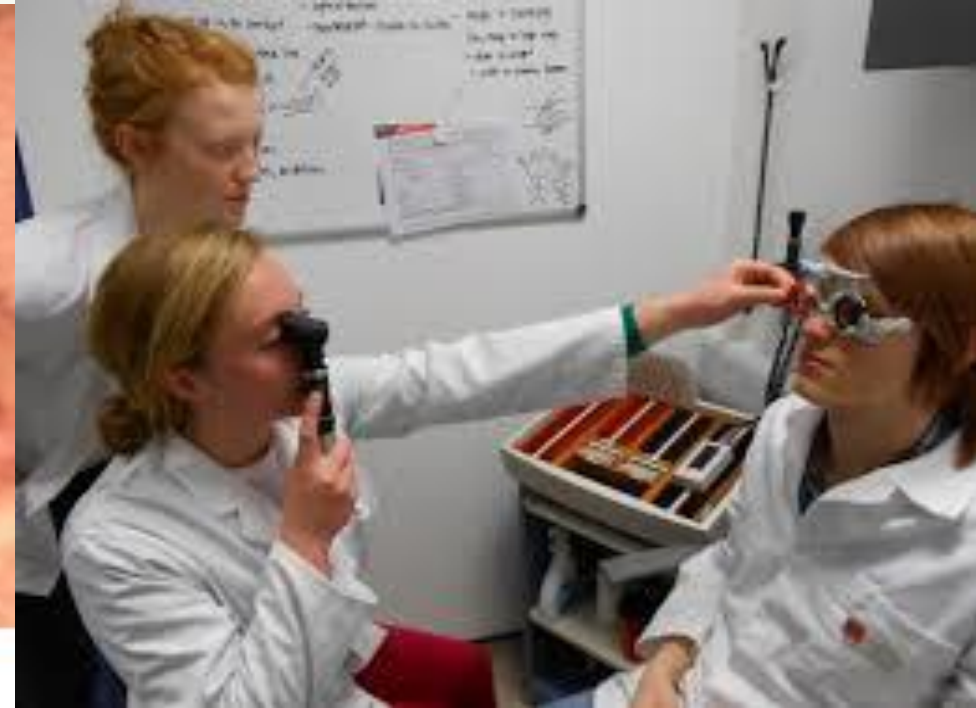
Pinhole




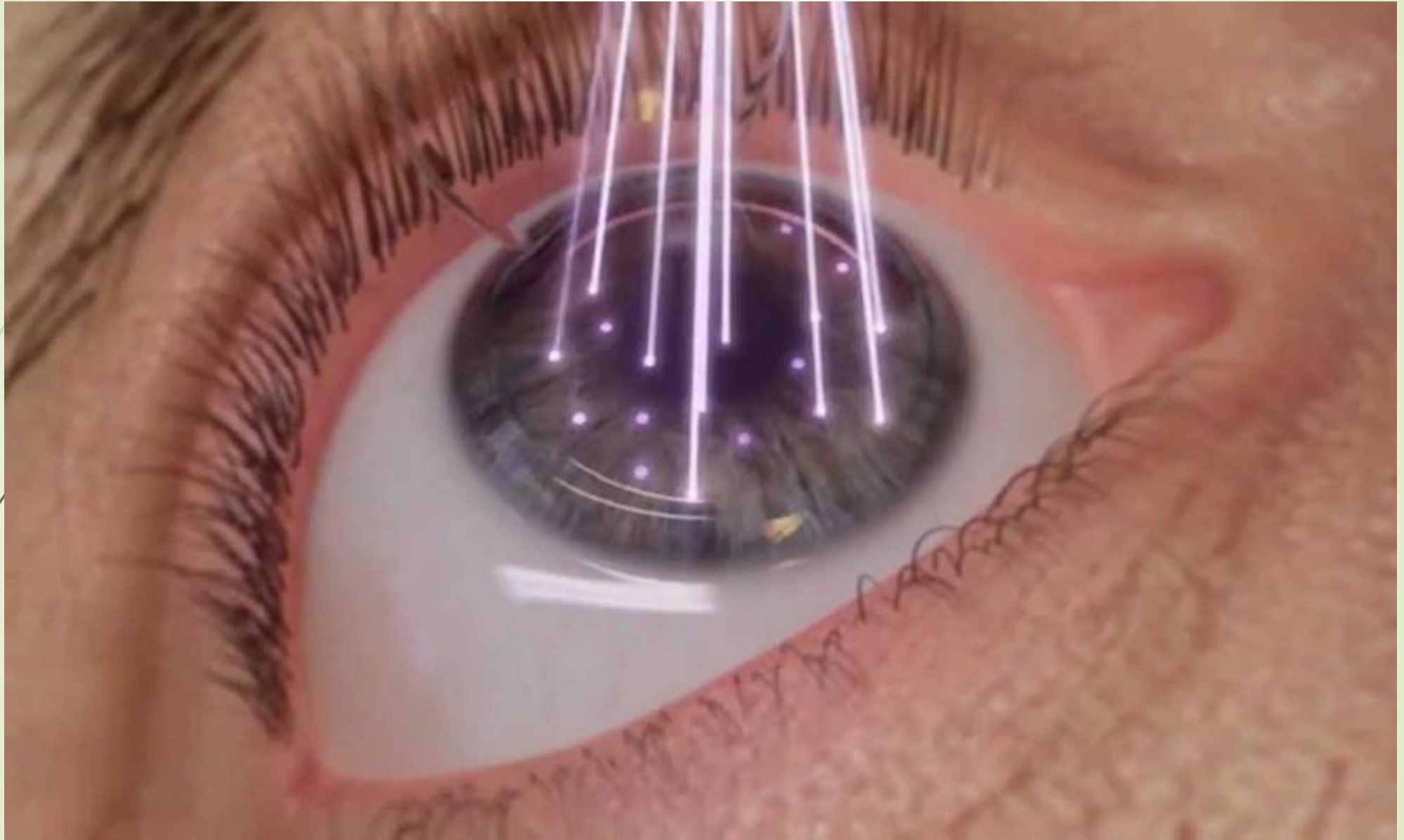
Retinoscopy

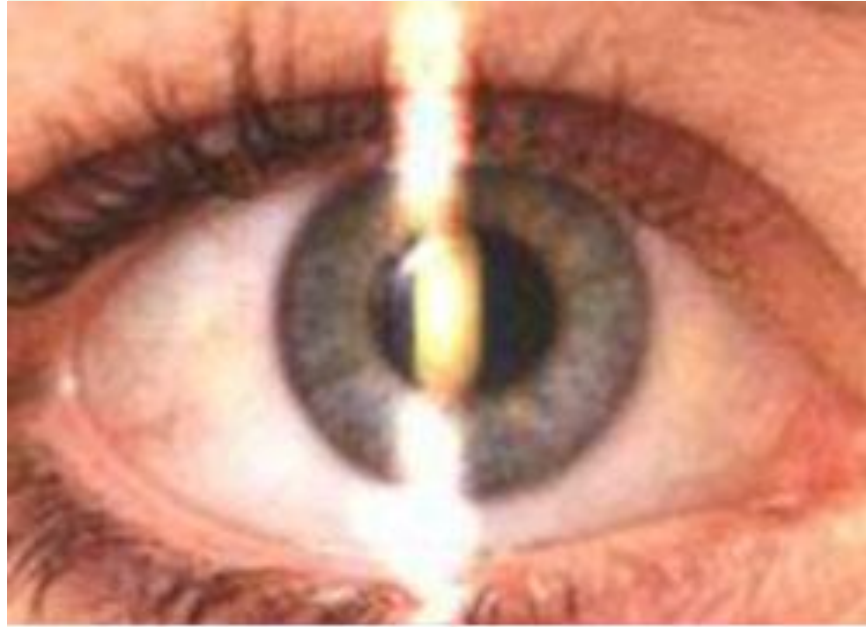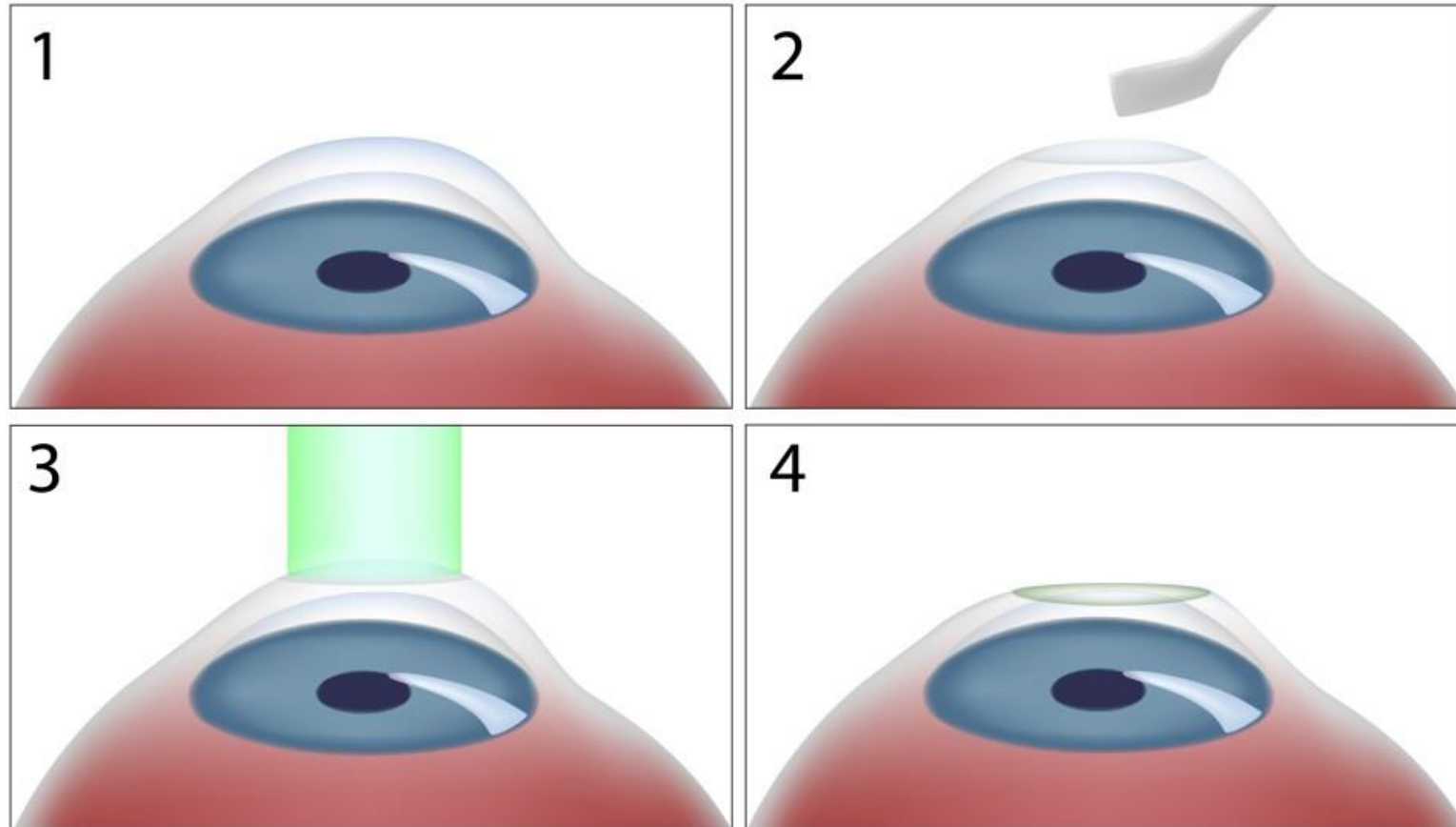


Fig. 1 A hand held instrument called a retinoscope projects a beam of light into the eye during a retinoscopy.










Photorefractive Keratectomy (PRK)



At the beginning of the procedure, the eye is anesthetized with topical eyedrops.



The surgeon then uses a device called Femto second Laser to create a corneal flap on the outer layer of the eye.



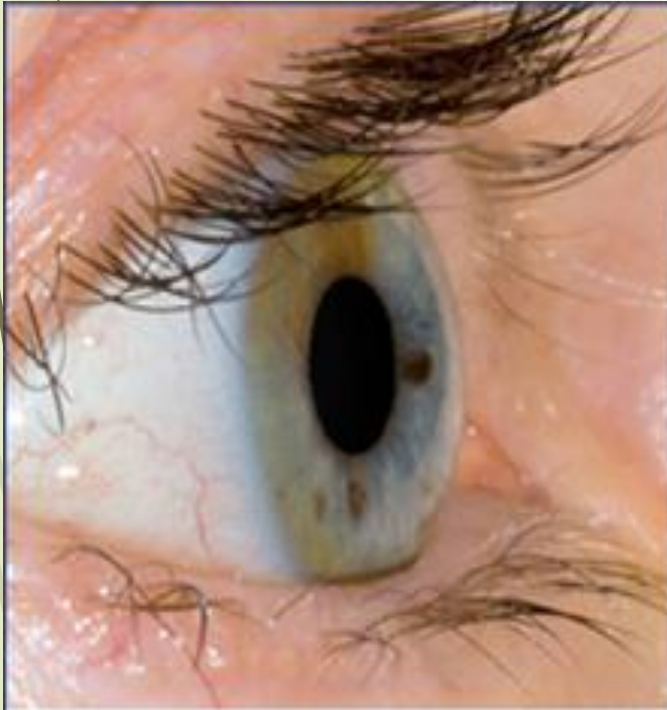
After the flap has been created, an excimer laser is used to reshape the cornea.



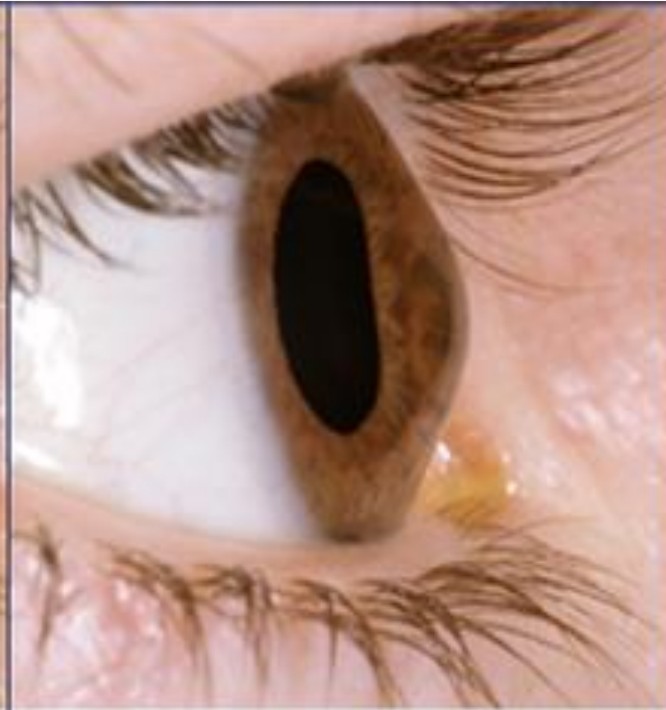The corneal flap is replaced.



The eye will heal by itself, and no stitches are necessary.




Normal Cornea




Keratoconic cornea

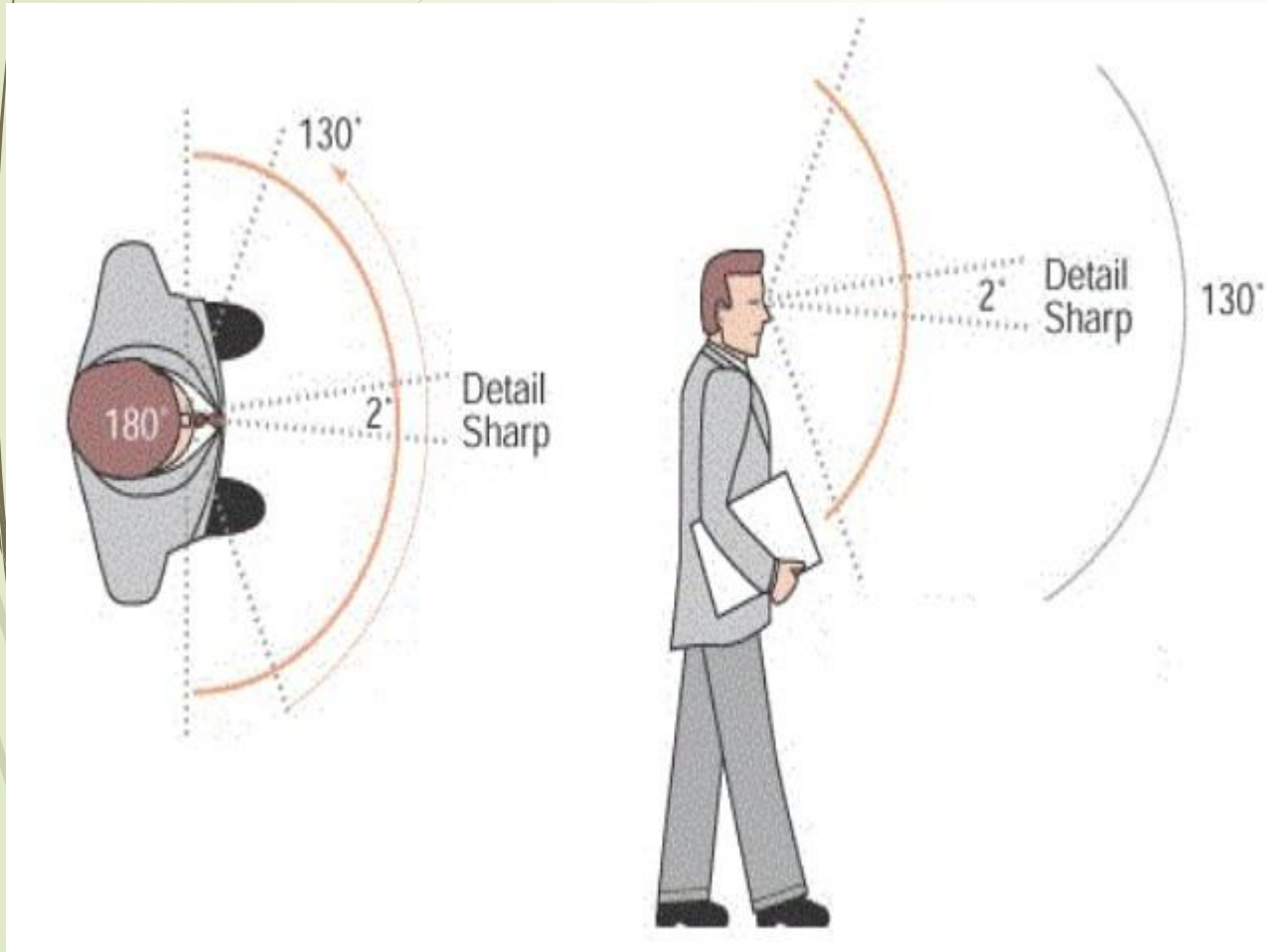
Normal cornea



Keratoconus



Visual Field

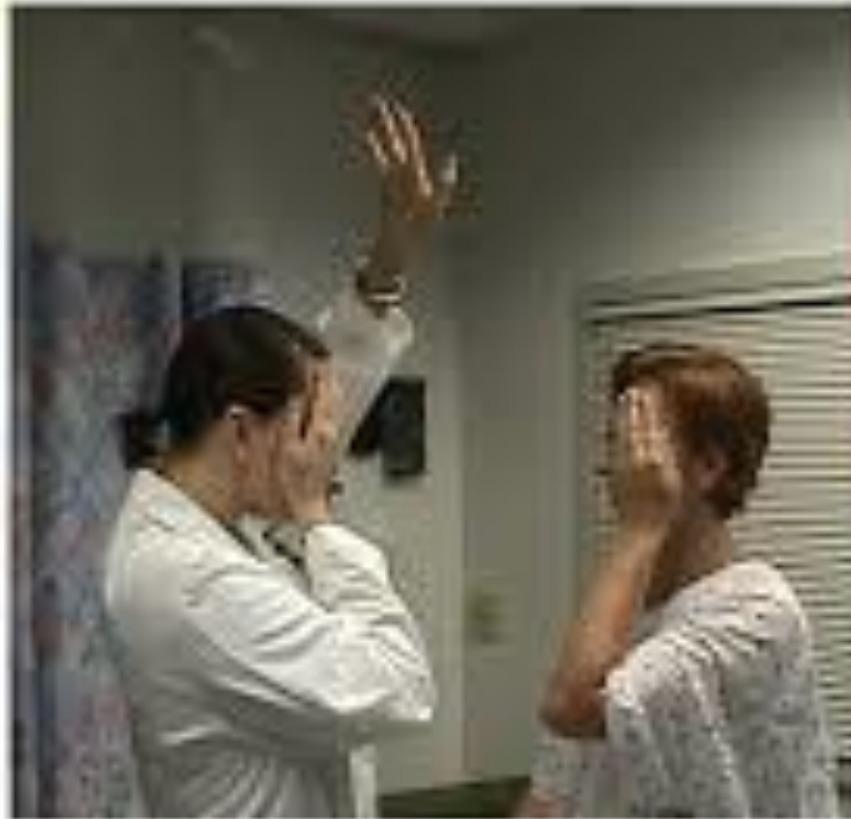

Classical limits (large, bright targets):

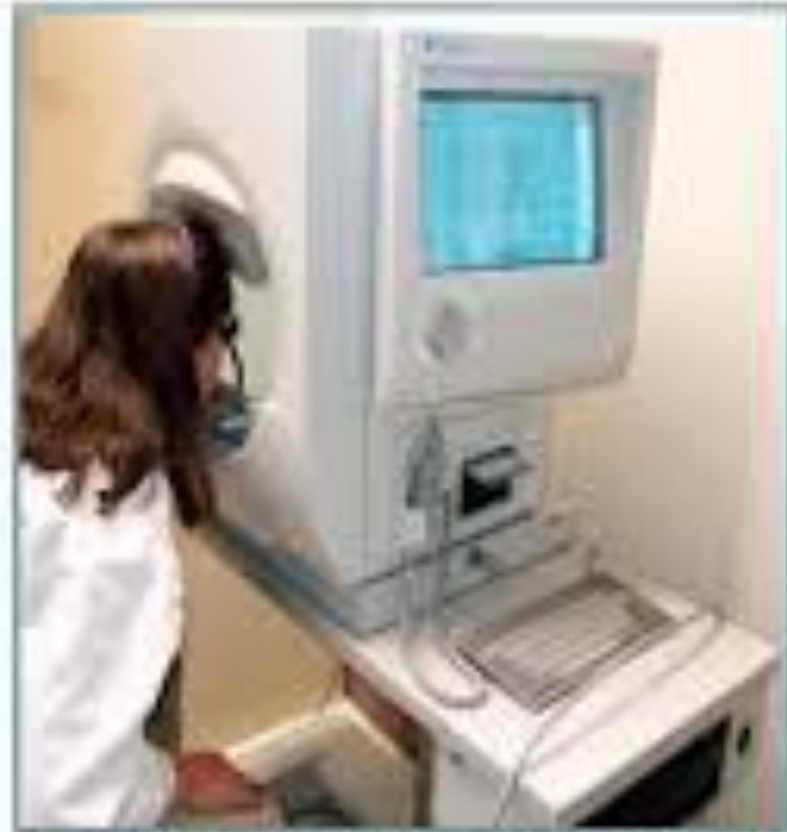- Superior $\sim 60^\circ$
- Inferior $\sim 75^\circ$
- Temporal $\sim 100^\circ$
- Nasal $\sim 60^\circ$

Normal limits of visual field

Diagram A shows a profile of a head with a 60-degree superior limit and a 75-degree inferior limit. Diagram B shows a top-down view of a head with a 100-degree temporal limit and a 60-degree nasal limit. Diagram C shows a side view of a head with a 100-degree temporal limit and a 60-degree nasal limit. Arrows labeled 'Temporal' and 'Nasal' indicate the direction of the field.



Confrontation visual field exam


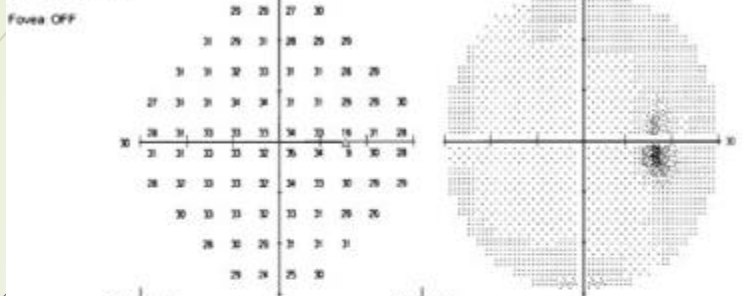


Humphrey automated perimetry

servignature

Single Field Analysis Eye: Right
 Name: _____ ID: _____ DOB: _____


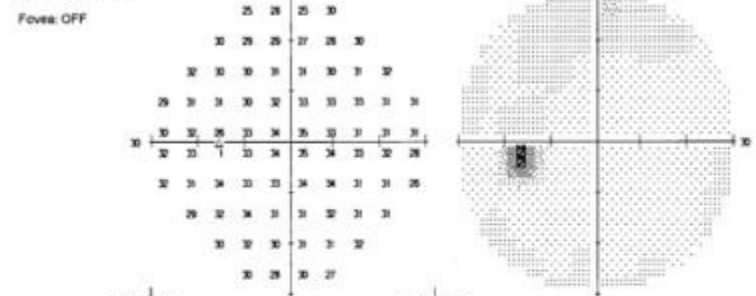
Central 30-2 Threshold Test
 Fixation Monitor: Gaze/Blindspot Stimulus: II, White Pupil Diameter: 7.2 mm Date: 04-19-2006
 Fixation Target: Central Background: 31.5 ASB Visual Acuity: _____ Time: 1:03 PM
 Fixation Losses: 0/12 Strategy: SITA-Fast RX: +0.00 DS DC X Age: 12
 False POS Errors: 2%
 False NEG Errors: 0%
 Test Duration: 04:27



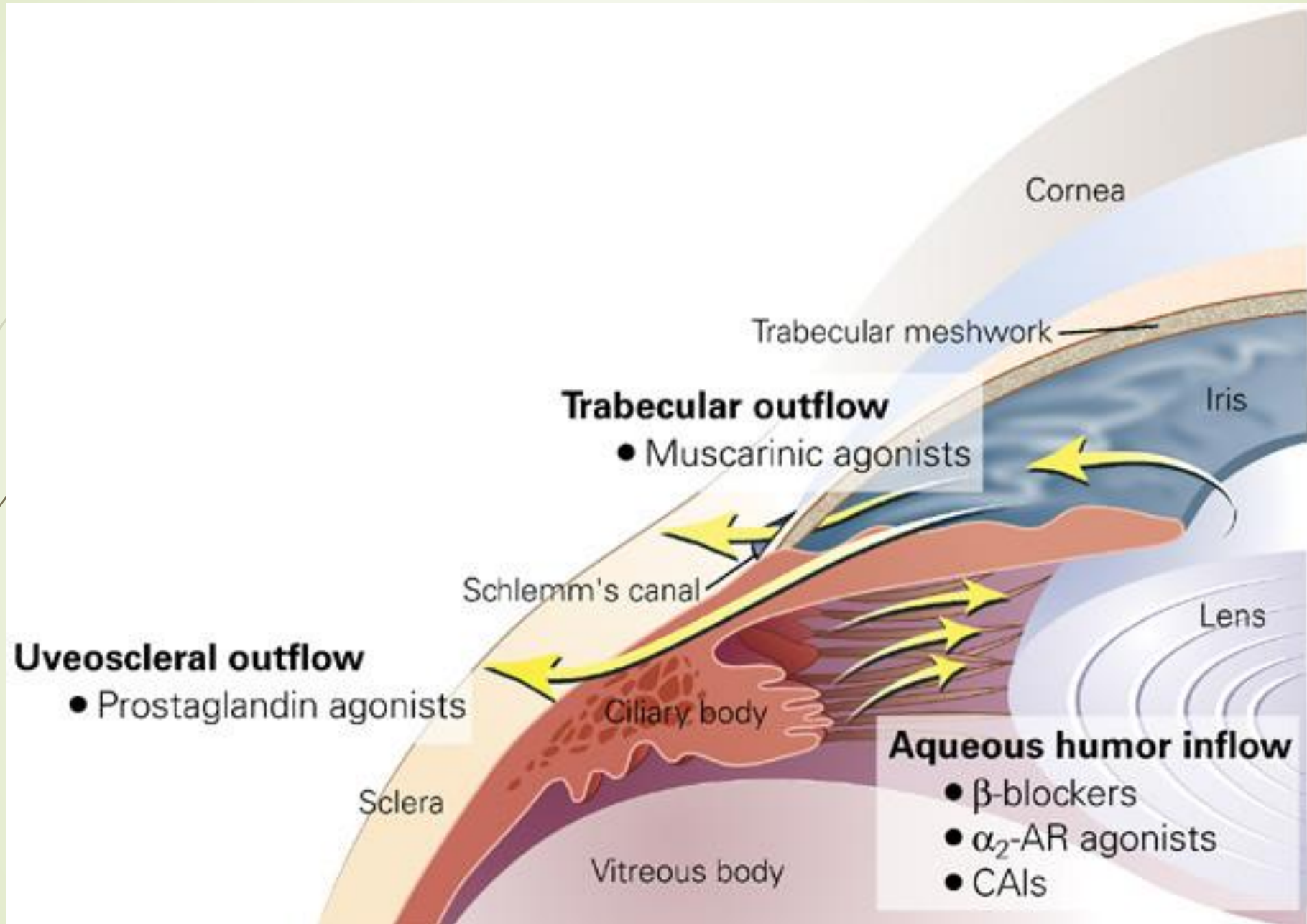
© 1994-98 Humphrey Systems
 HFA II 750-T128-Rev. A10.2

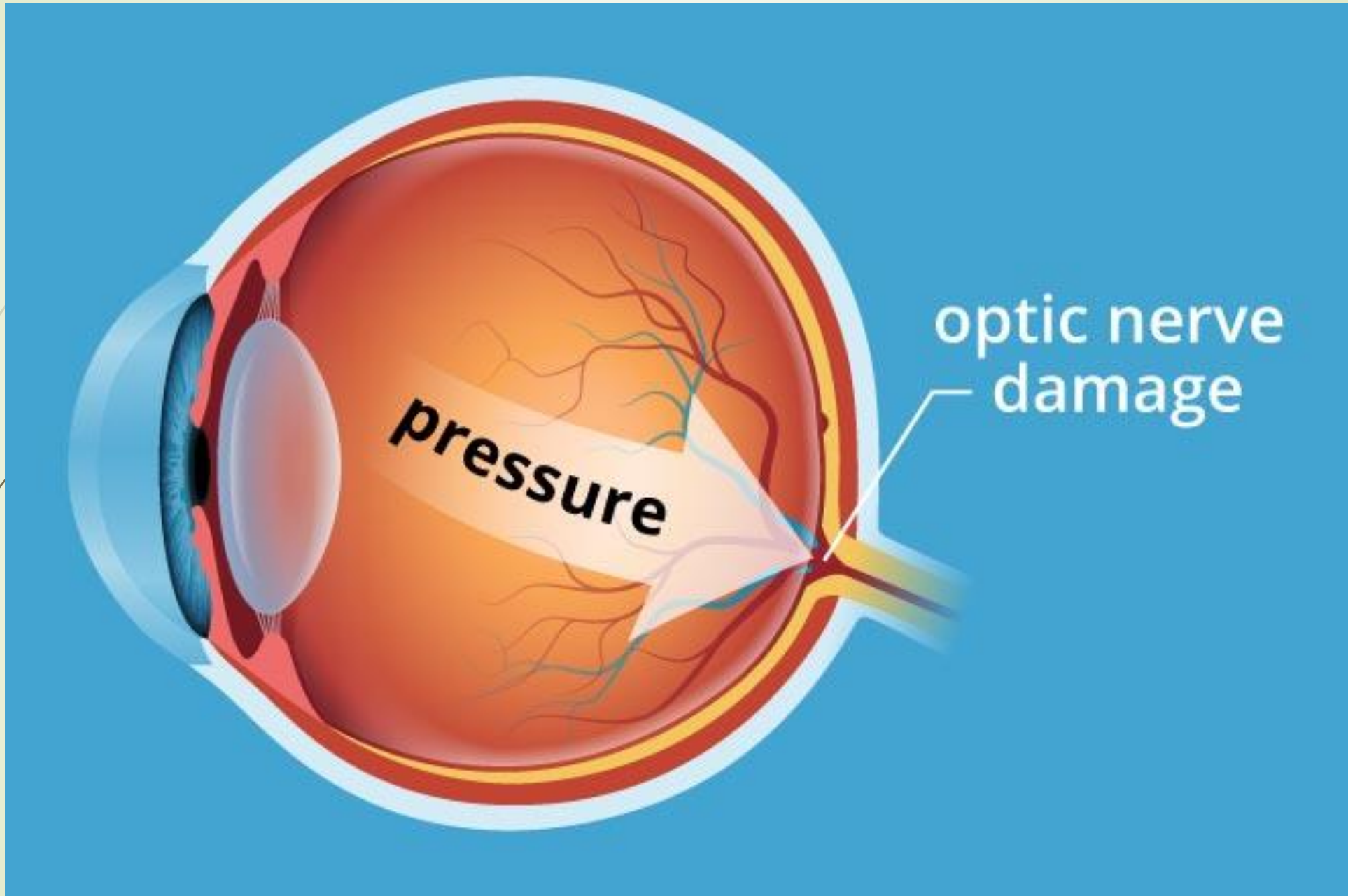
Single Field Analysis Eye: Left
 Name: _____ ID: _____ DOB: _____

Central 30-2 Threshold Test
 Fixation Monitor: Gaze/Blindspot Stimulus: II, White Pupil Diameter: 3.8 mm Date: 04-19-2006
 Fixation Target: Central Background: 31.5 ASB Visual Acuity: _____ Time: 1:11 PM
 Fixation Losses: 1/11 Strategy: SITA-Fast RX: +0.00 DS DC X Age: 12
 False POS Errors: 5%
 False NEG Errors: 0%
 Test Duration: 04:01



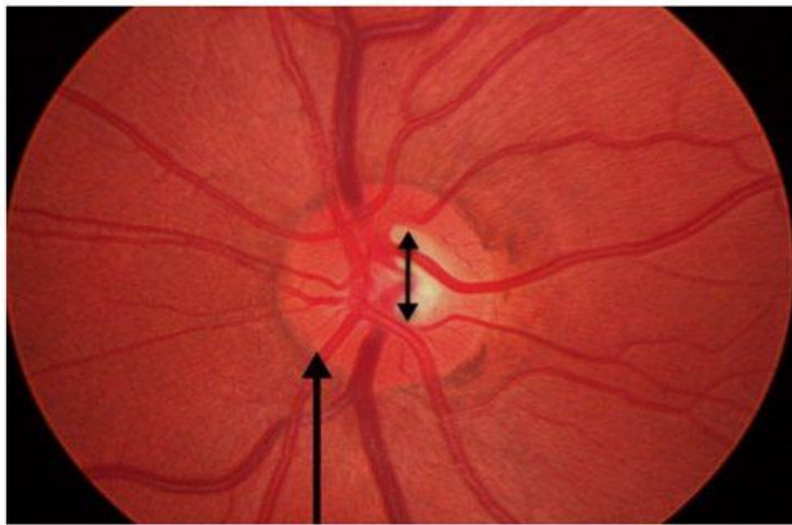
© 1994-98 Humphrey Systems
 HFA II 750-T128-Rev. A10.2



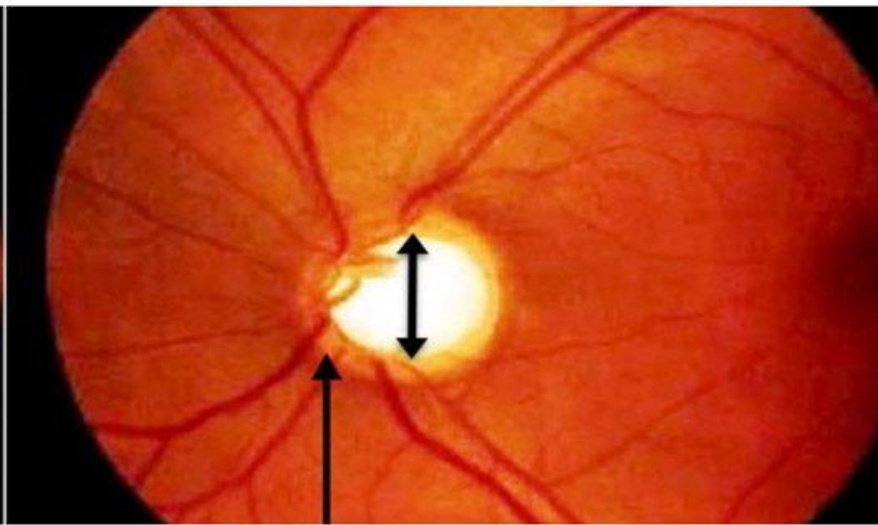


pressure

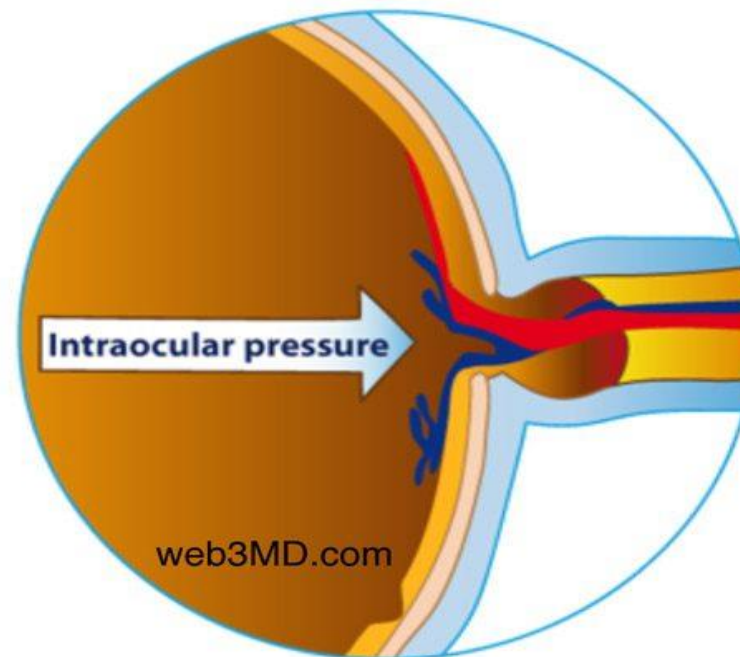
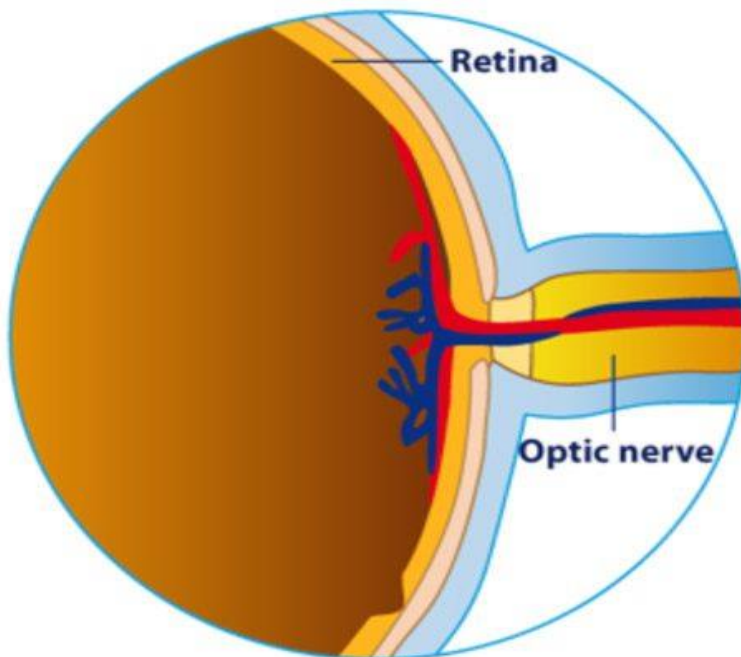
optic nerve
damage



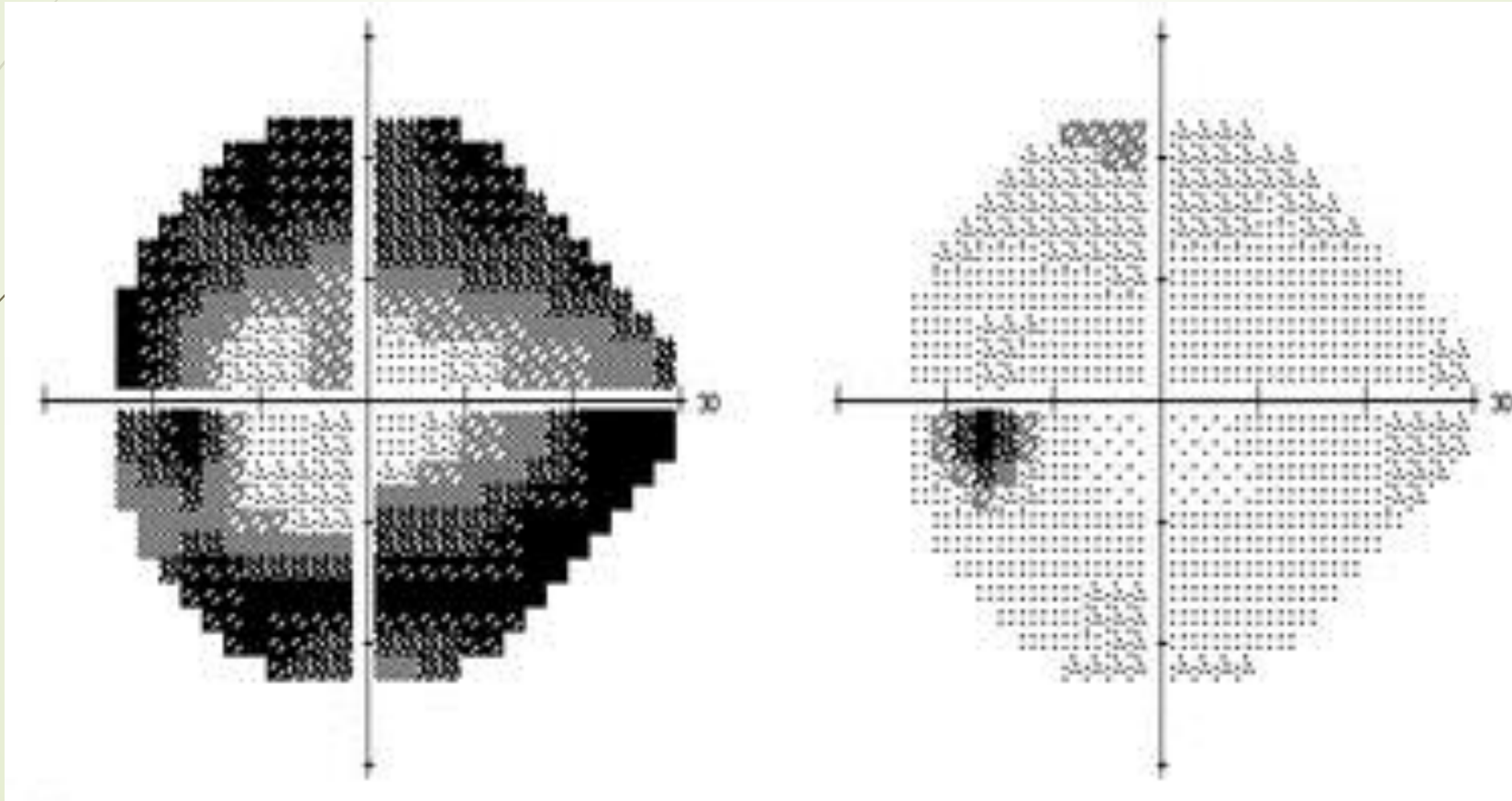
Healthy eye with a normal optic nerve head



Glaucoma eye with glaucomatous cupping of the the nerve head





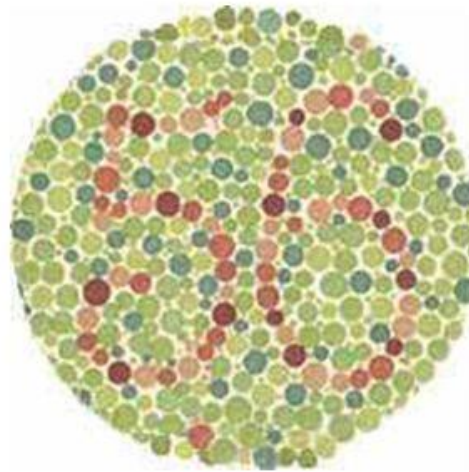



Advanced glaucoma





Tunnel Vision



Ishihara test for color blindness







V	R	S	K	D	R
N	H	C	S	O	K
S	C	N	O	Z	V
C	N	H	Z	O	K
N	O	D	V	H	R
C	D	N	Z	S	V
K	C	H	O	D	K
R	S	Z	H	V	R

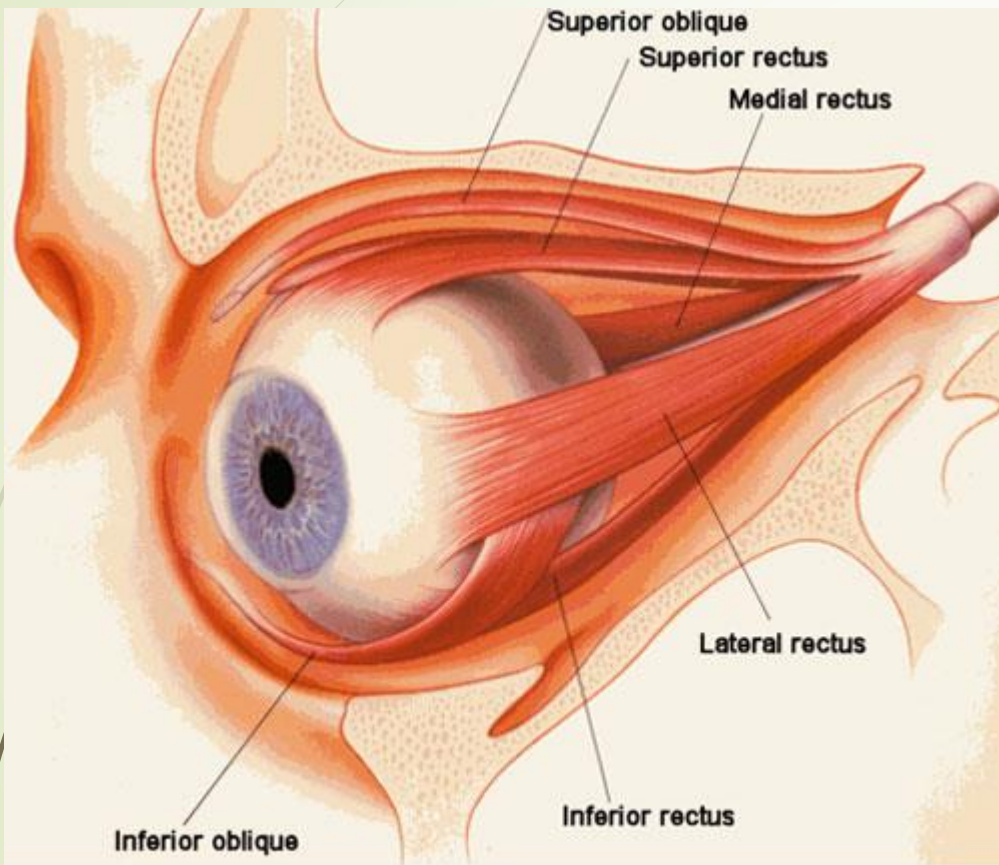
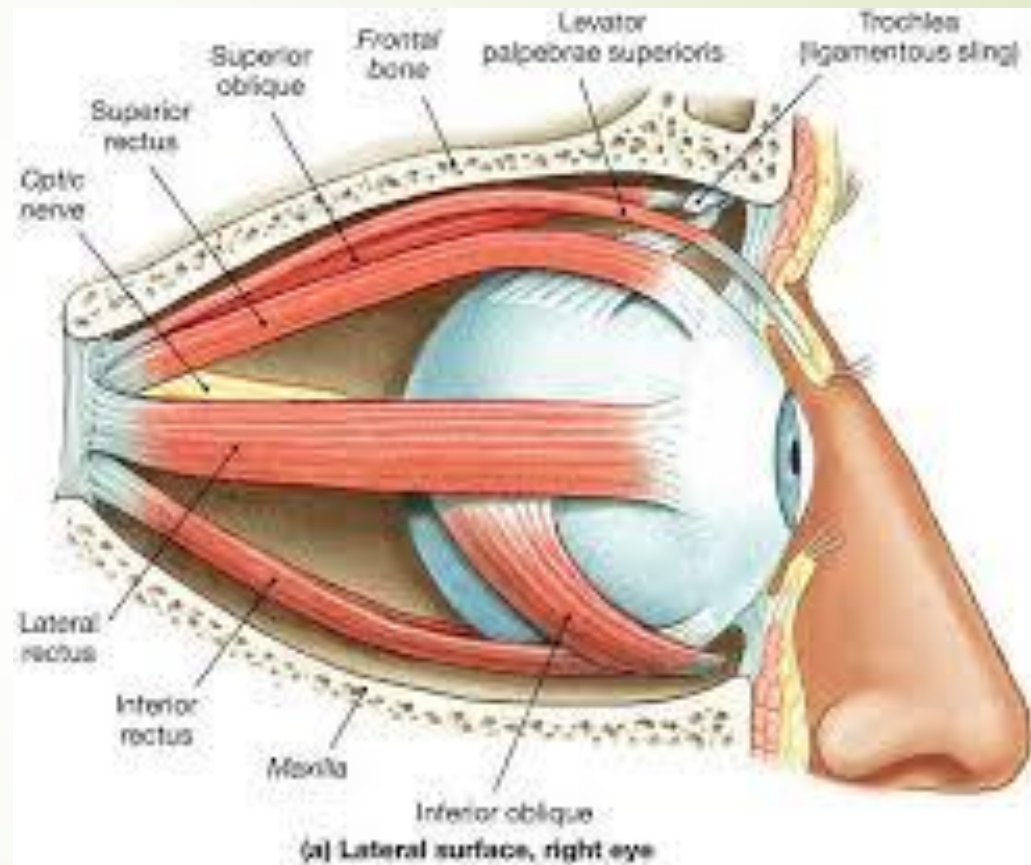
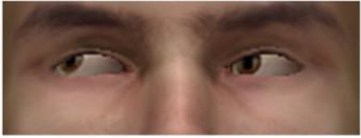

Fig. 1 Extraocular Muscle Anatomy

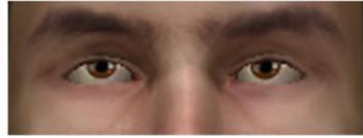

Ocular Motility Examination

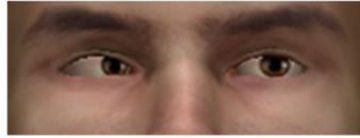Right and Up



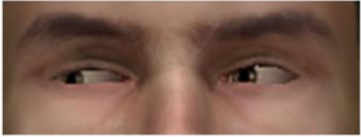
Up



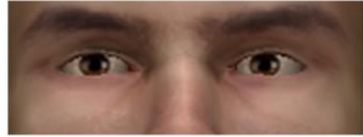Left and Up



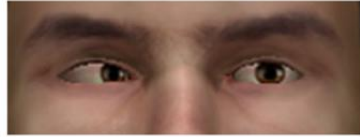Right



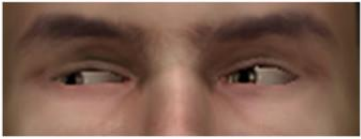
Primary Position



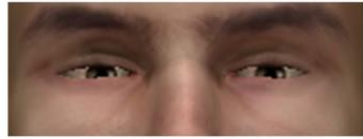Left



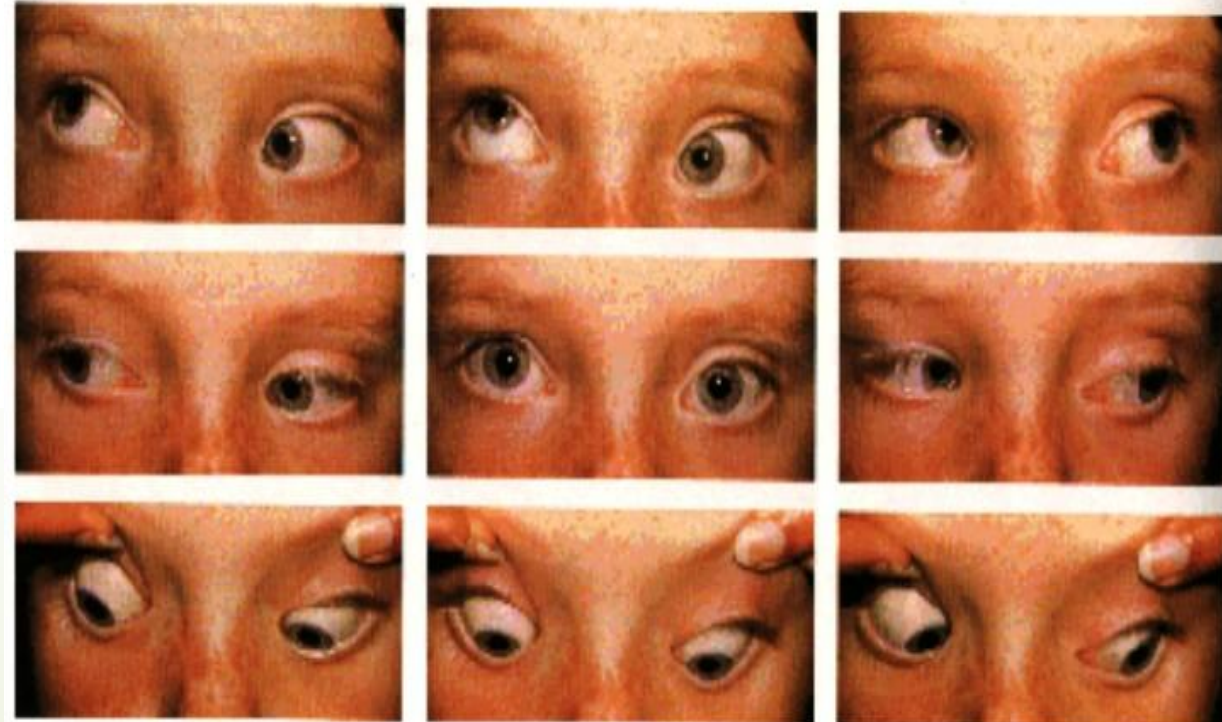
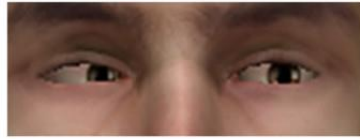Right and Down



Down

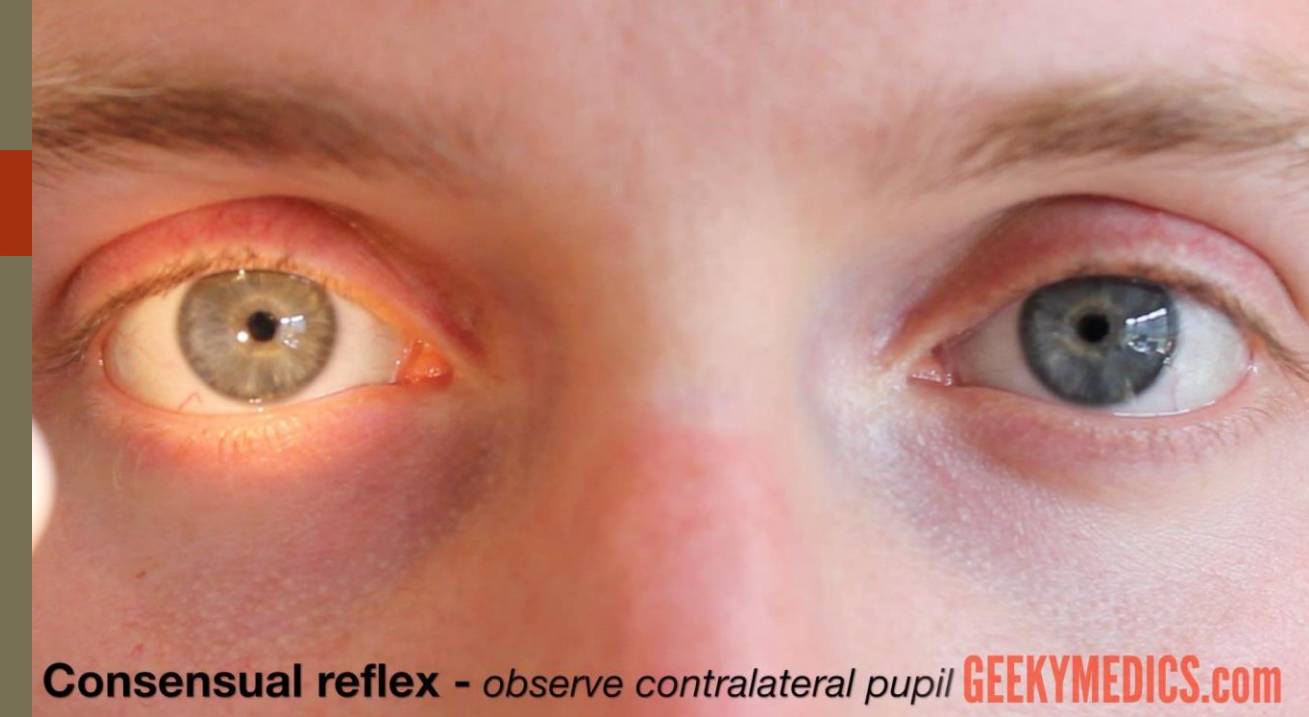

Left and Down

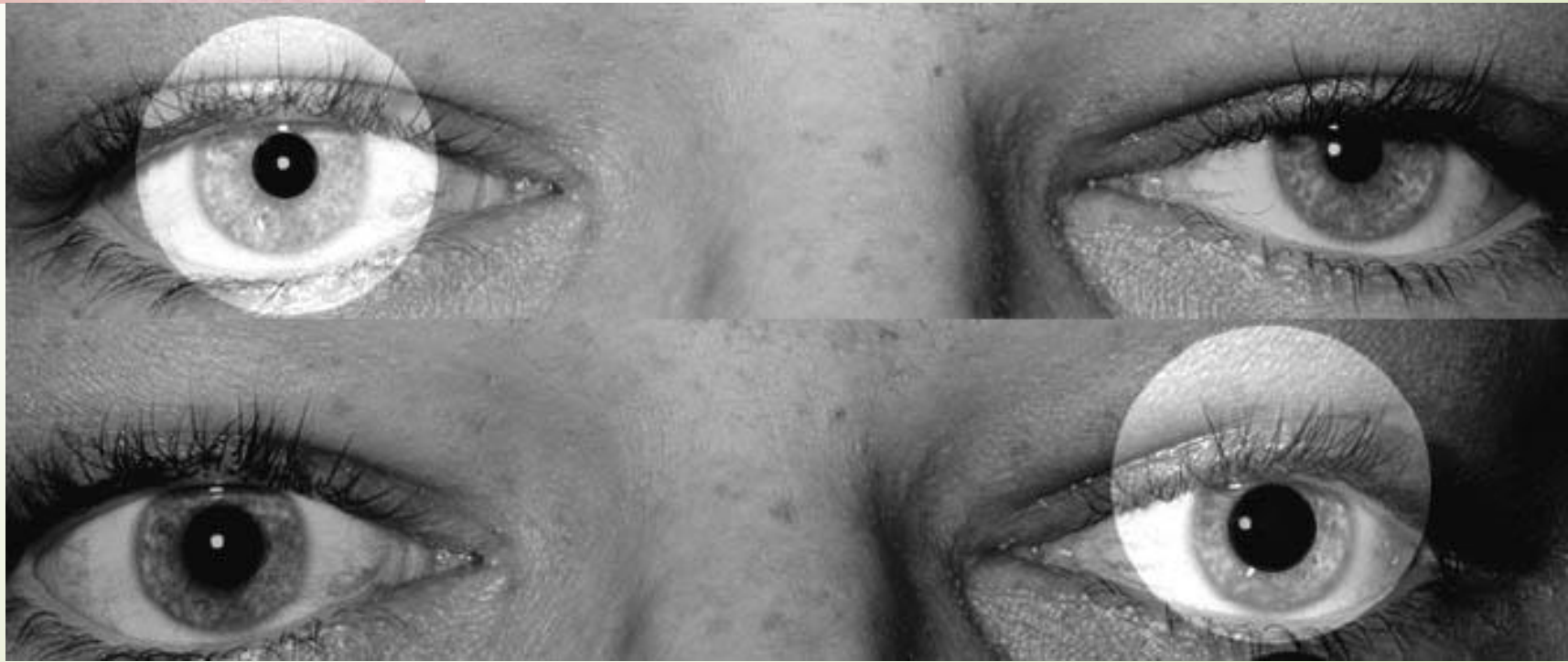

Pupillary Examination





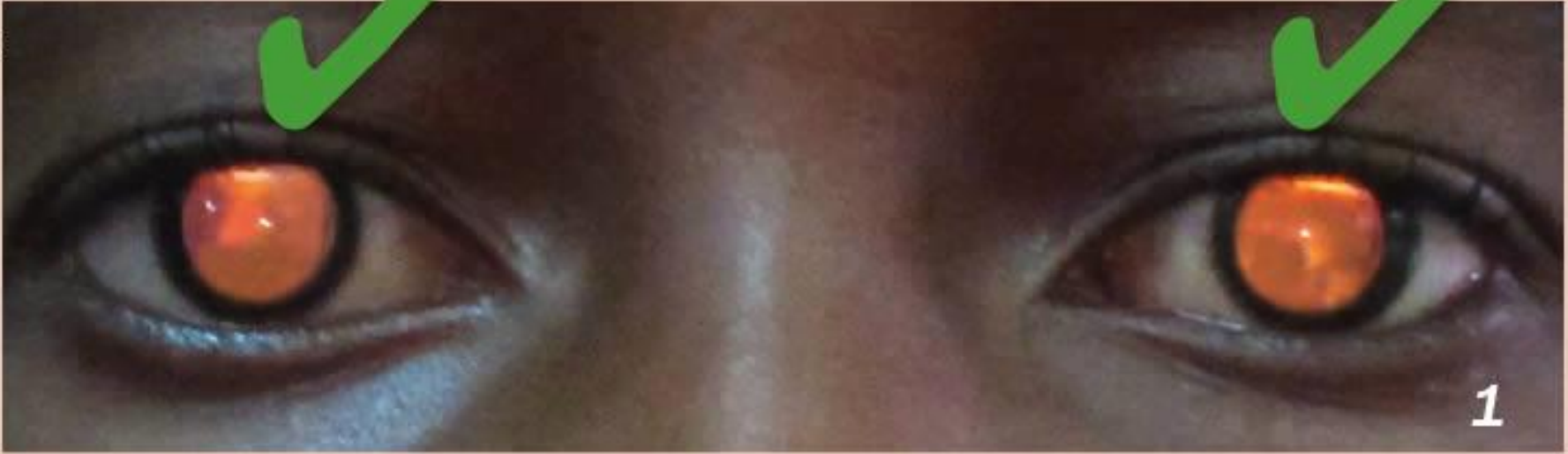RAPD



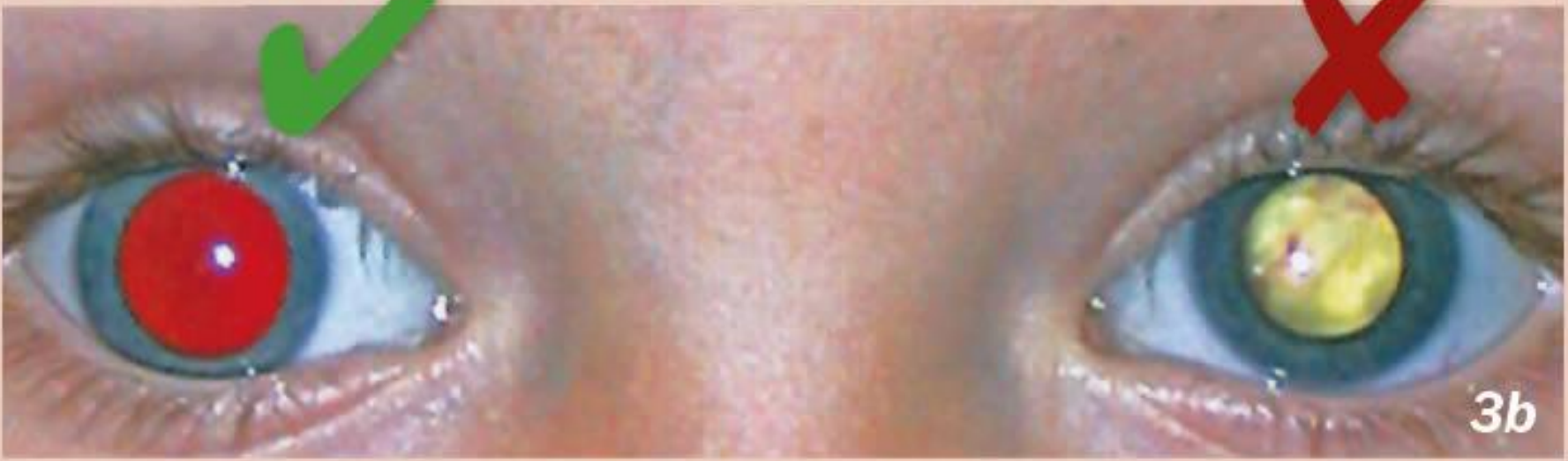Corneal light reflex

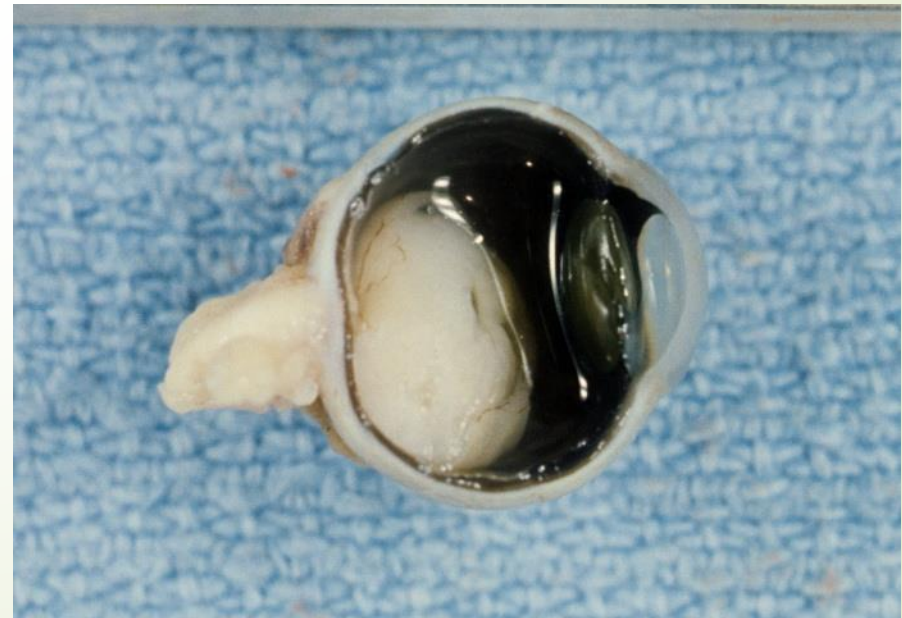
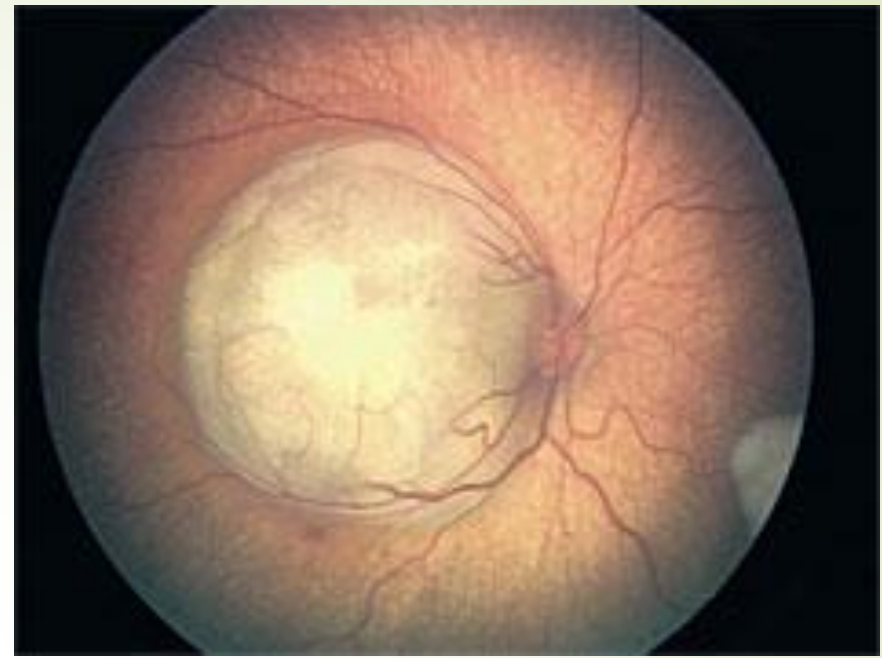
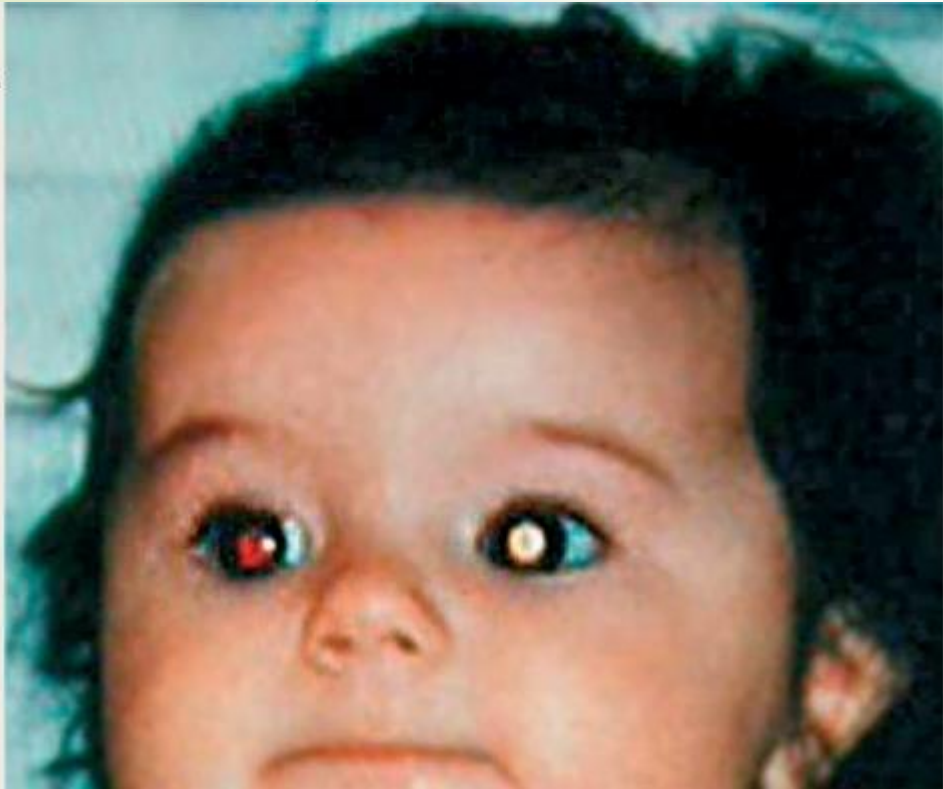

Heiko Philippin



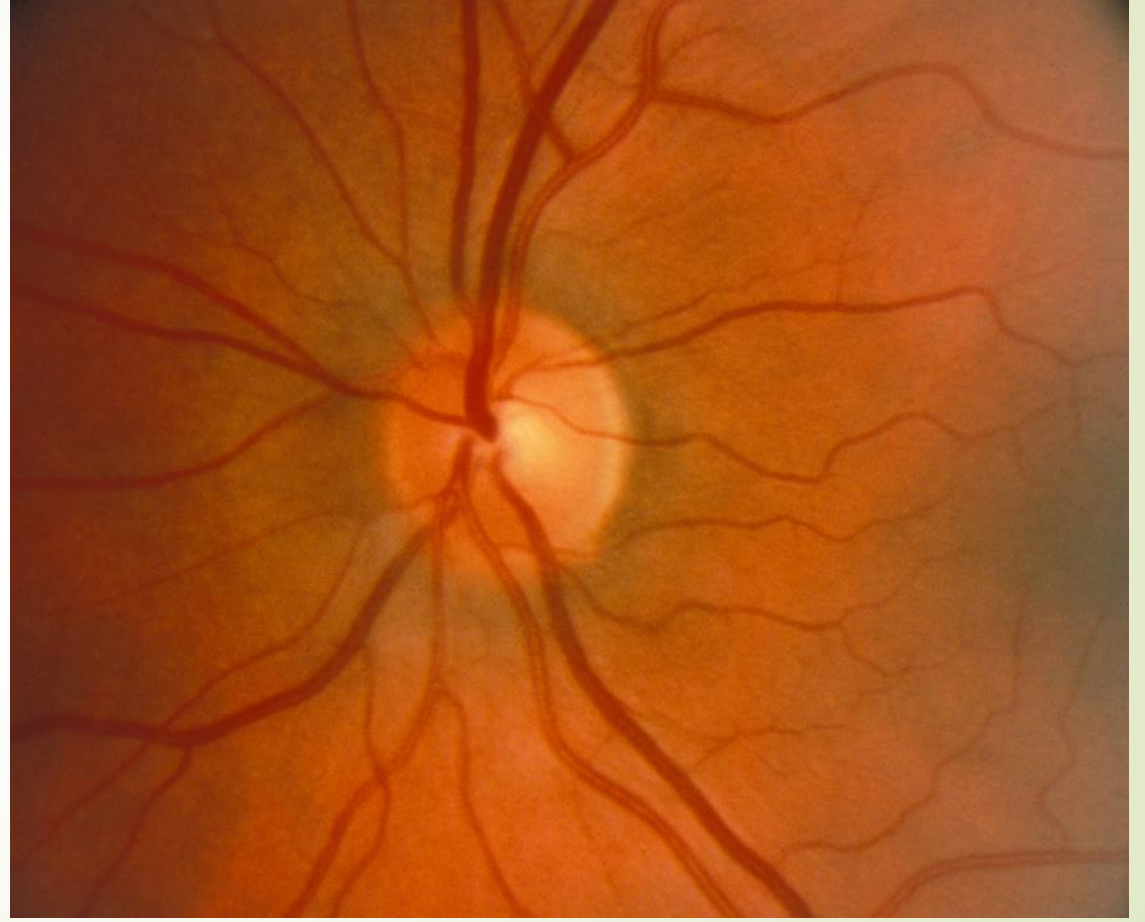
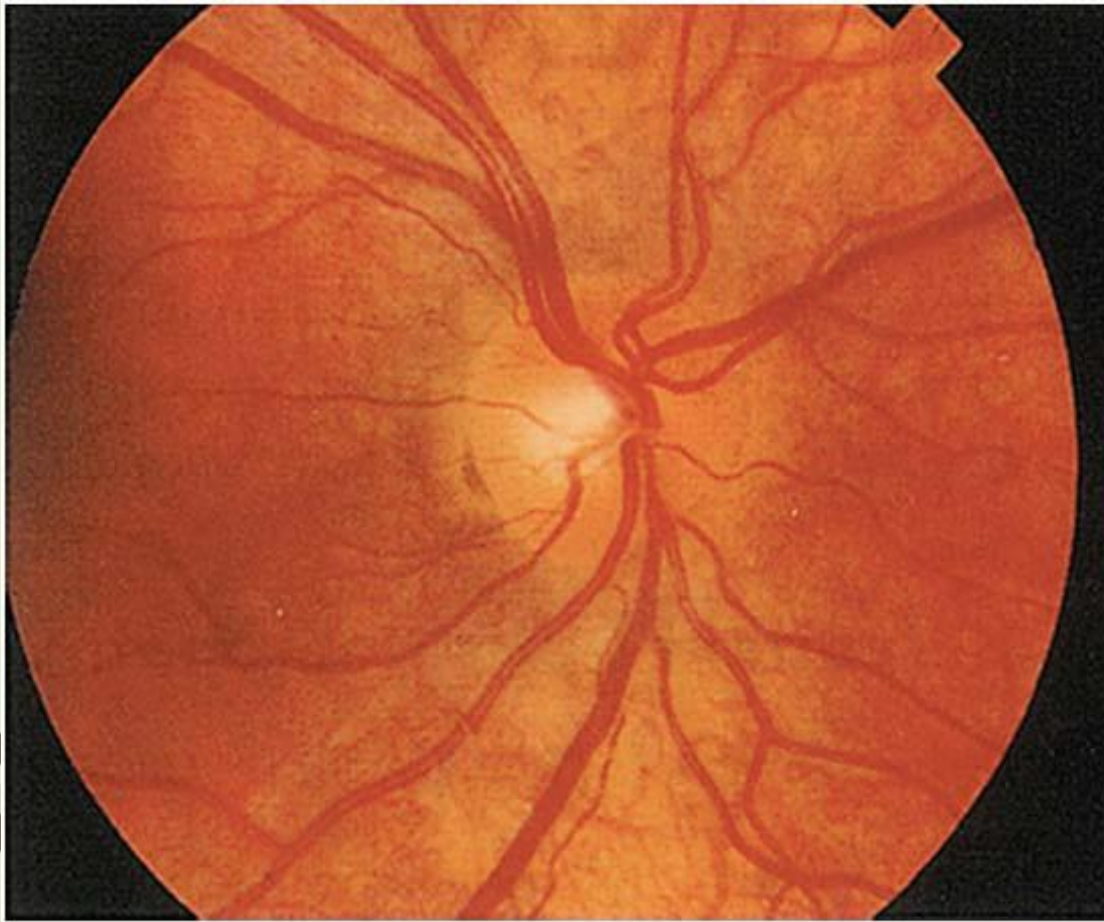
© Childhood Eye Cancer Trust

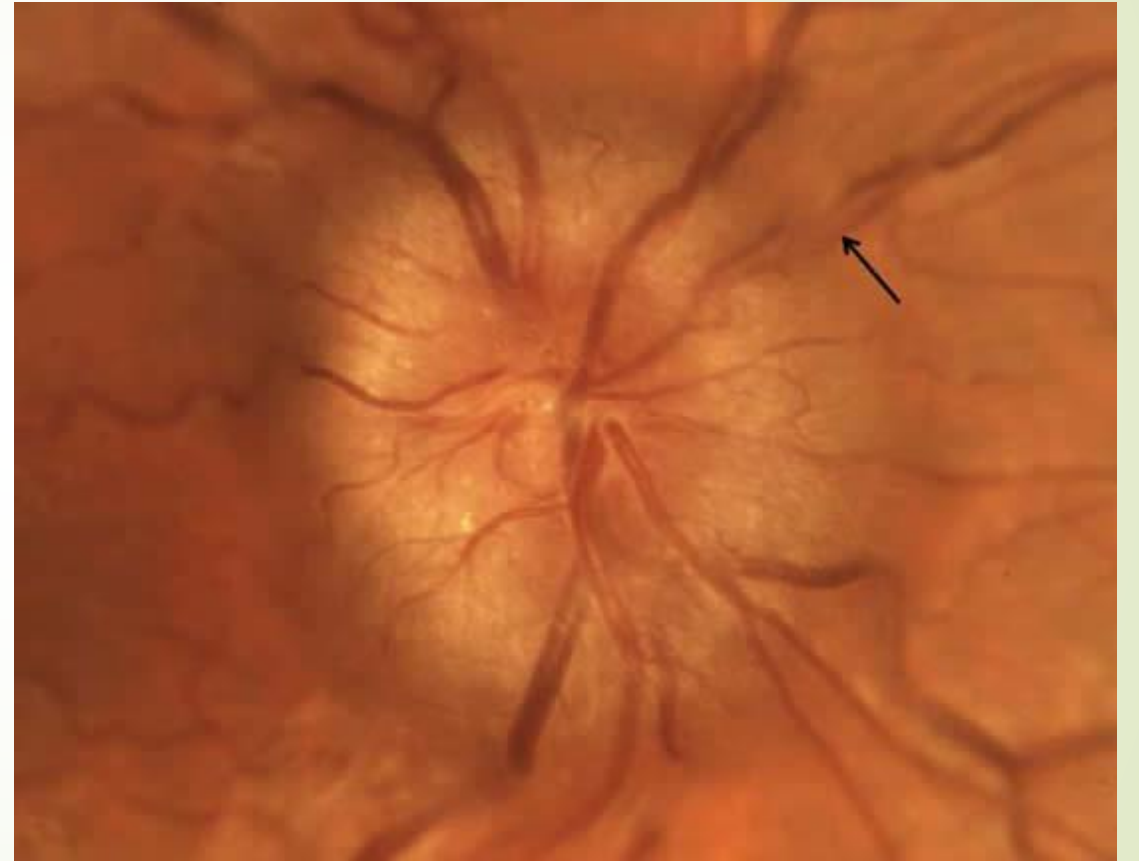
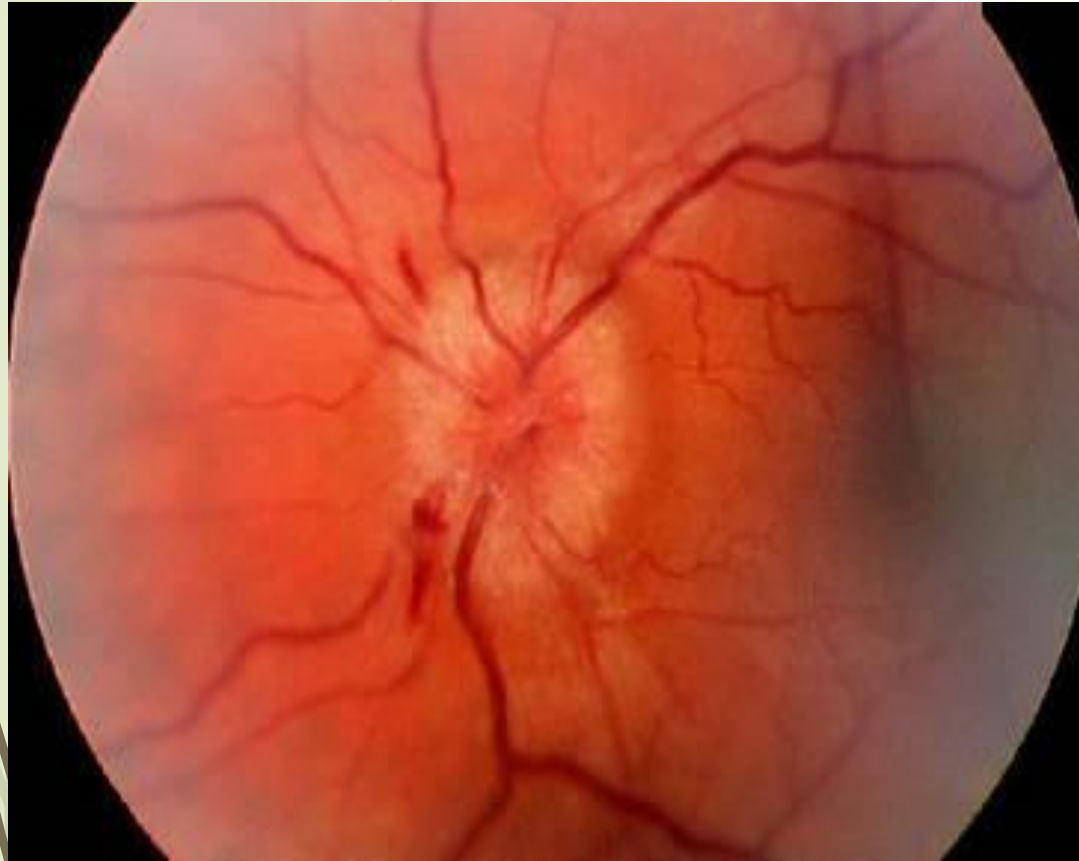

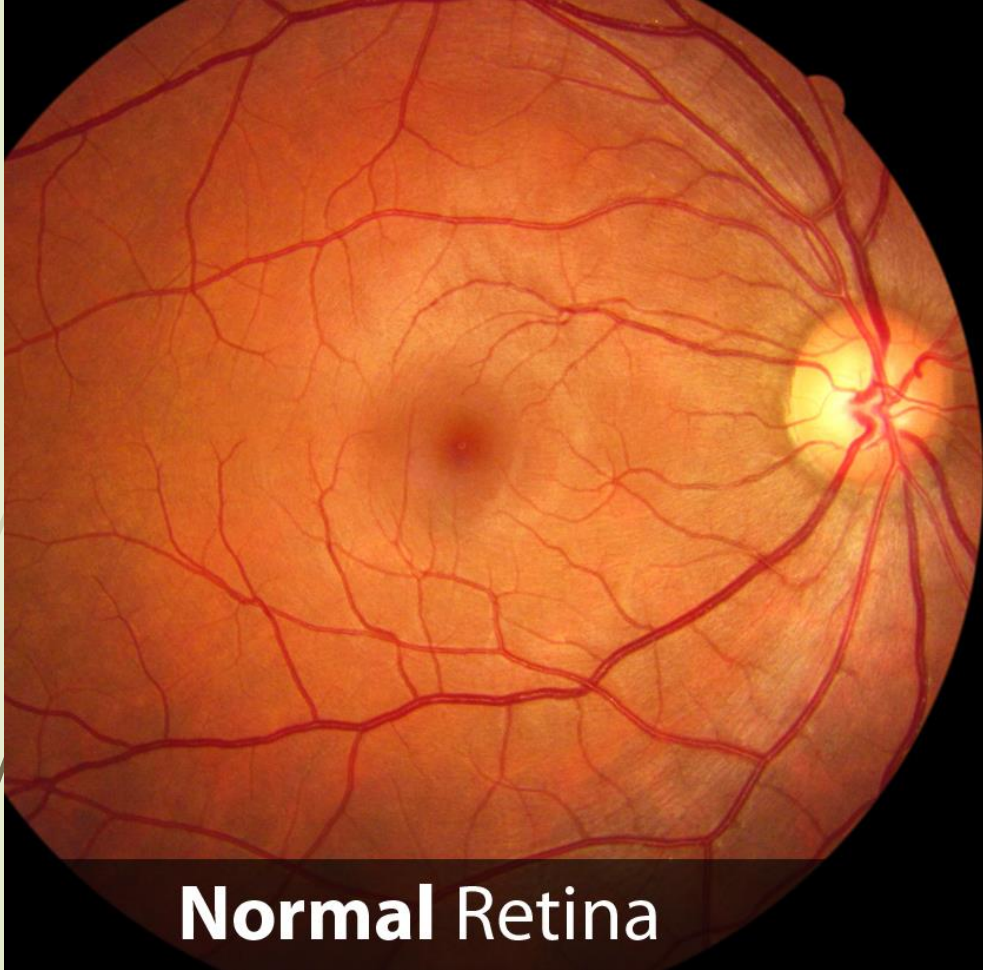


Direct Ophthalmoscope

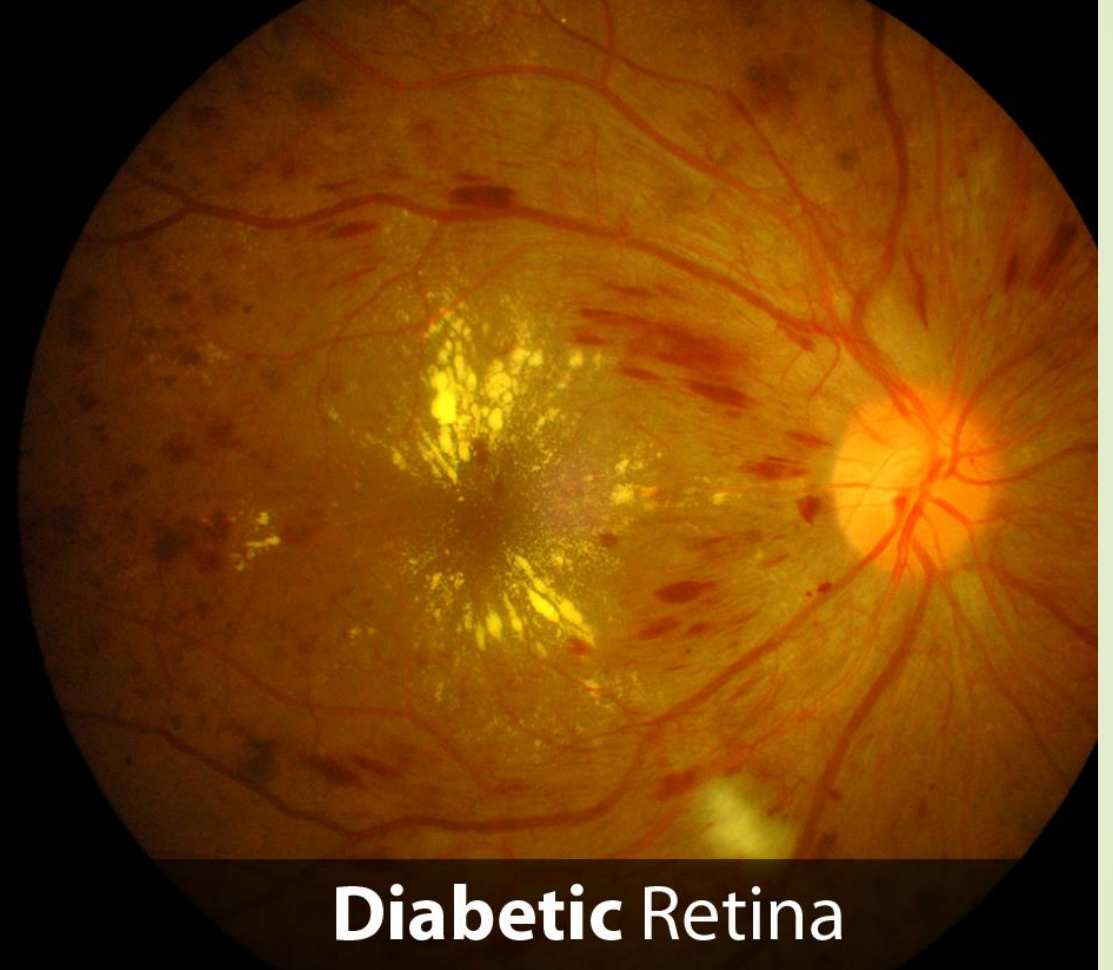







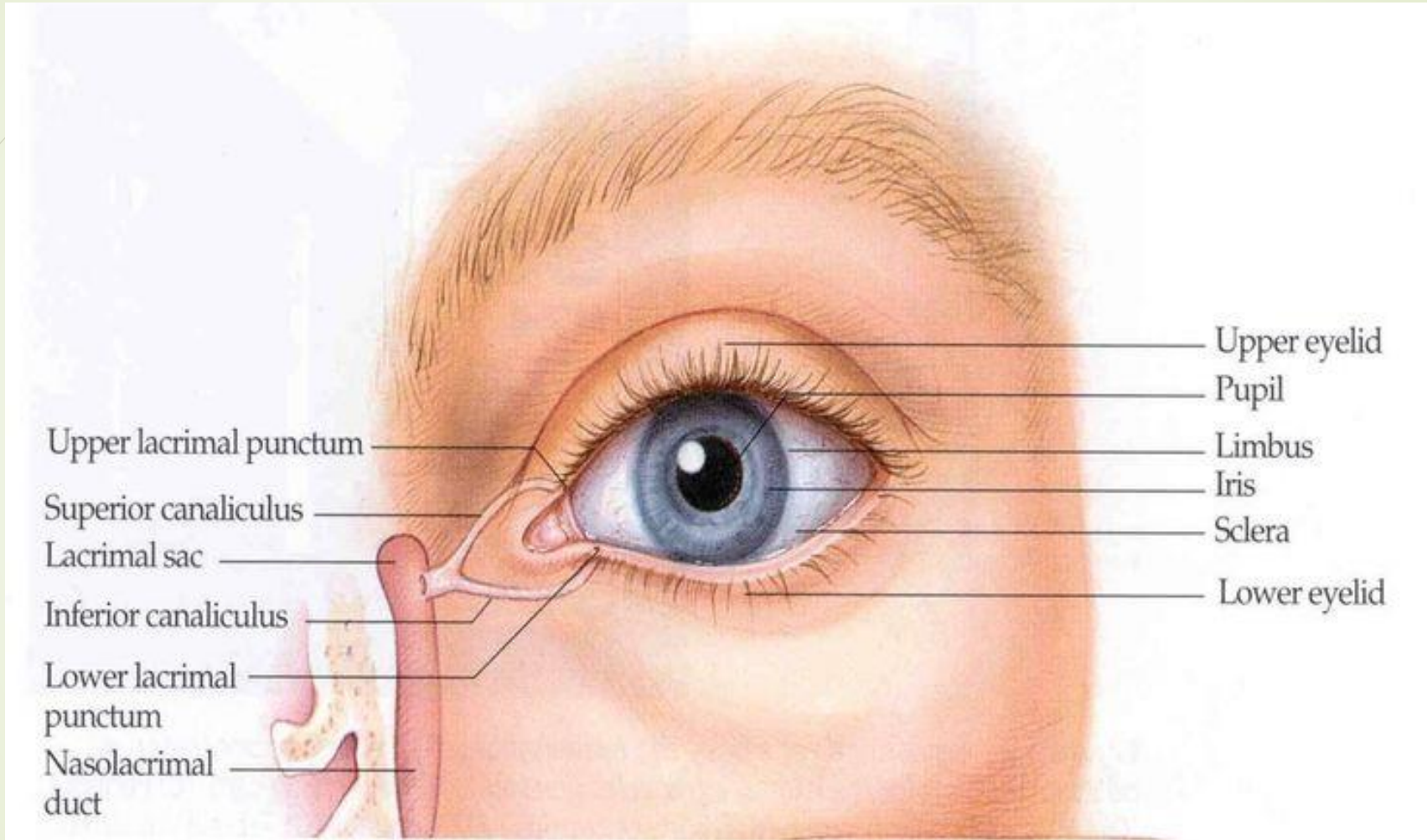
Normal Retina

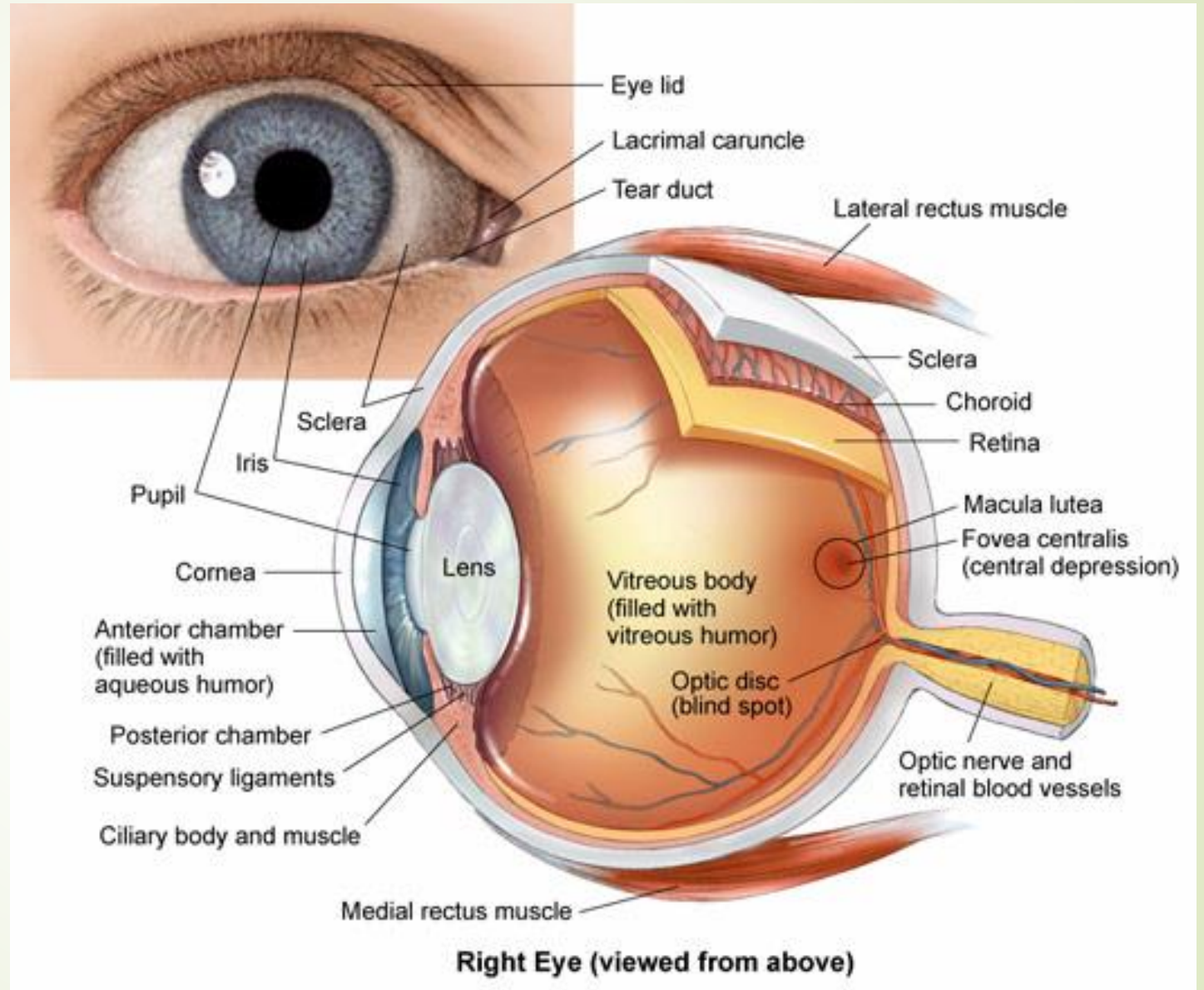
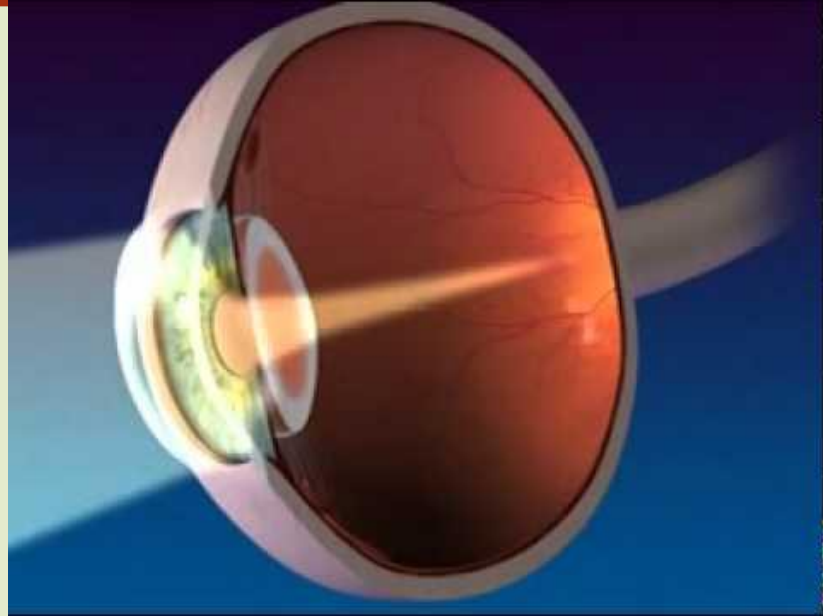


Diabetic Retina

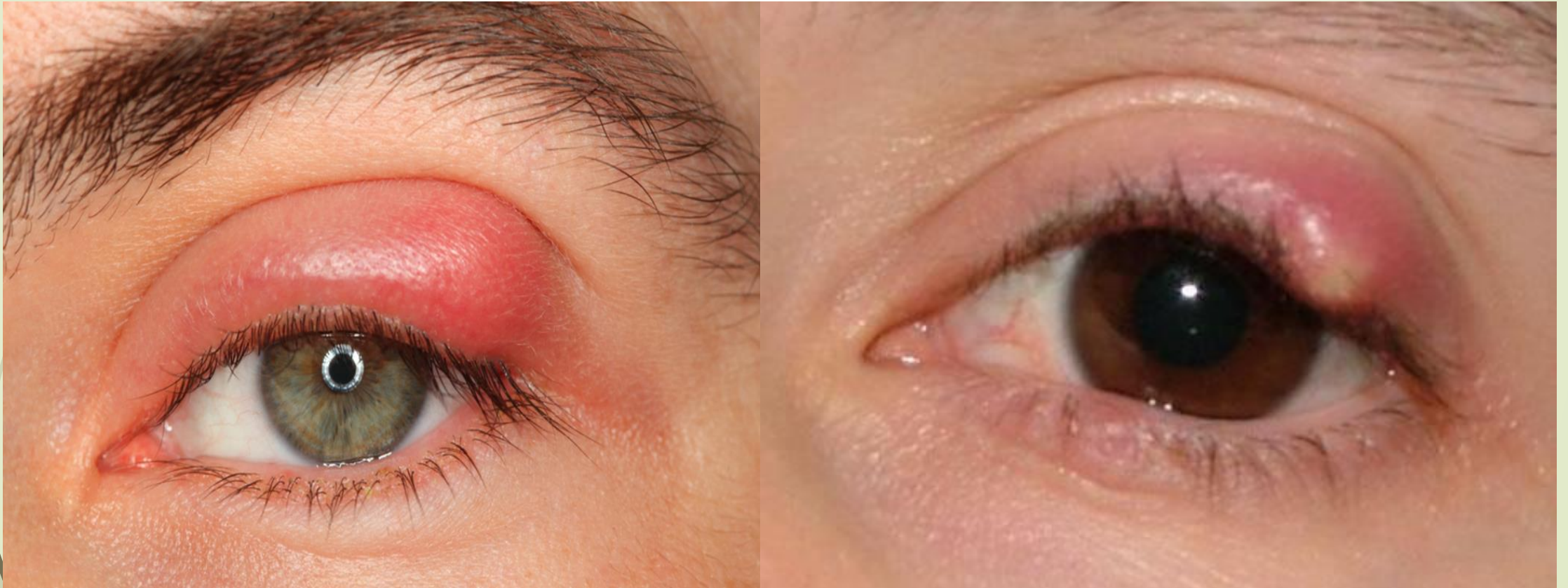


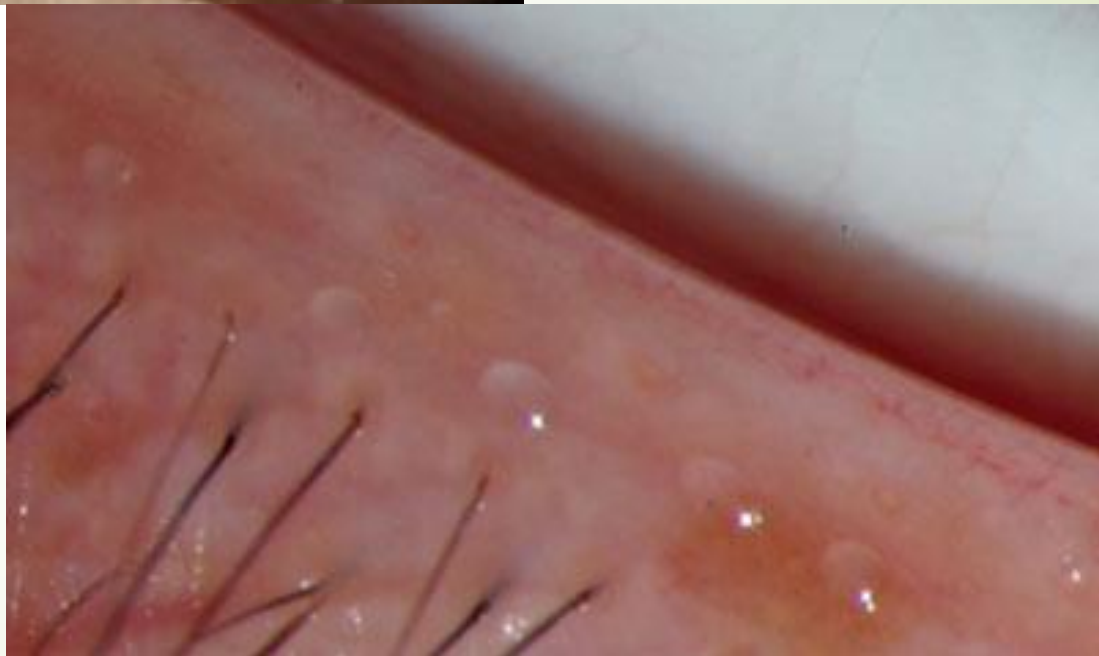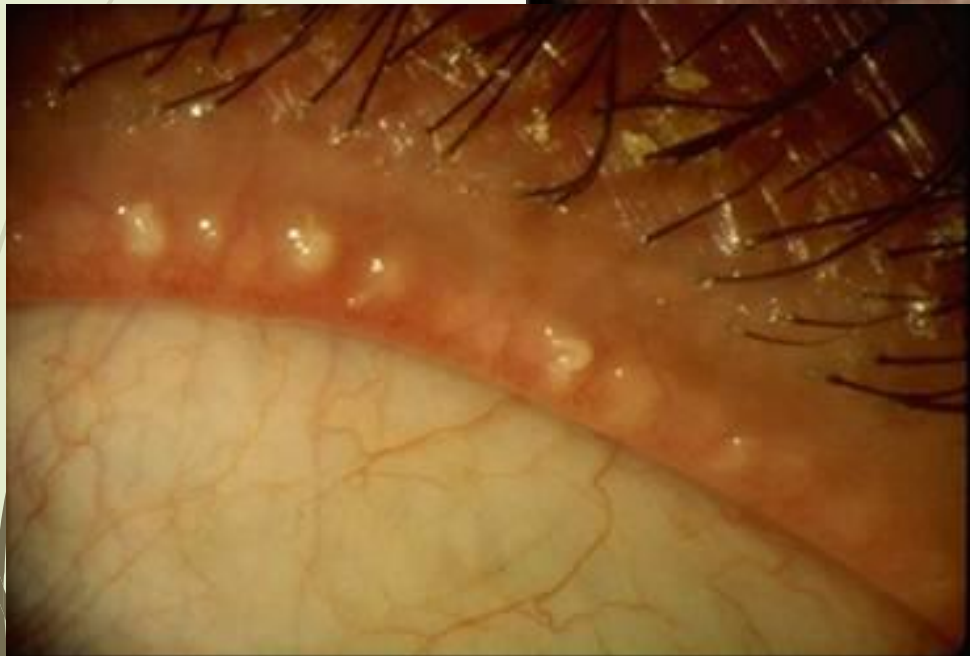
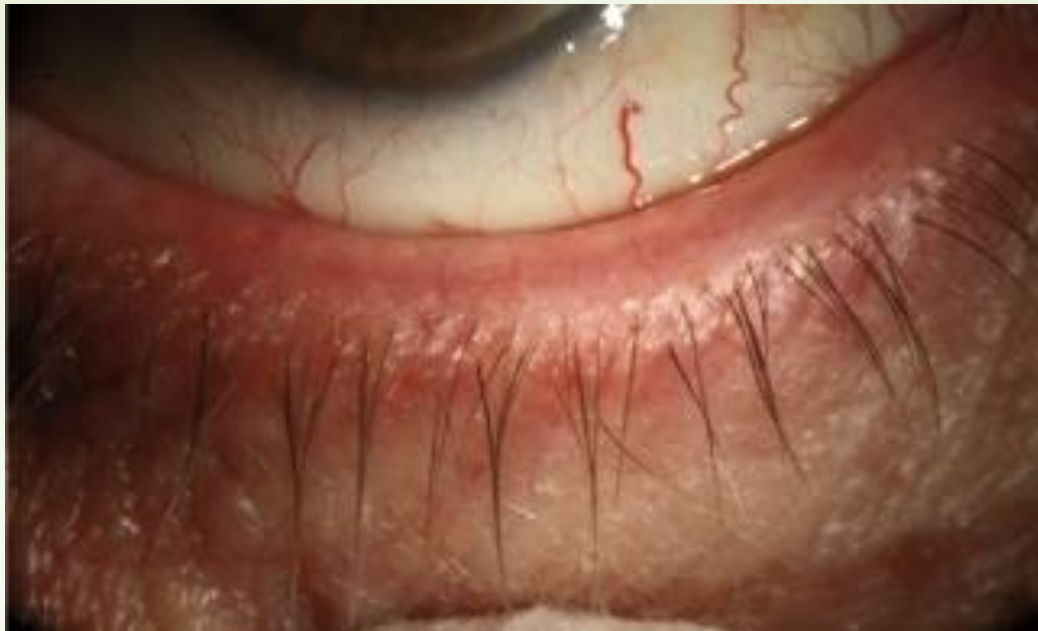External Examination





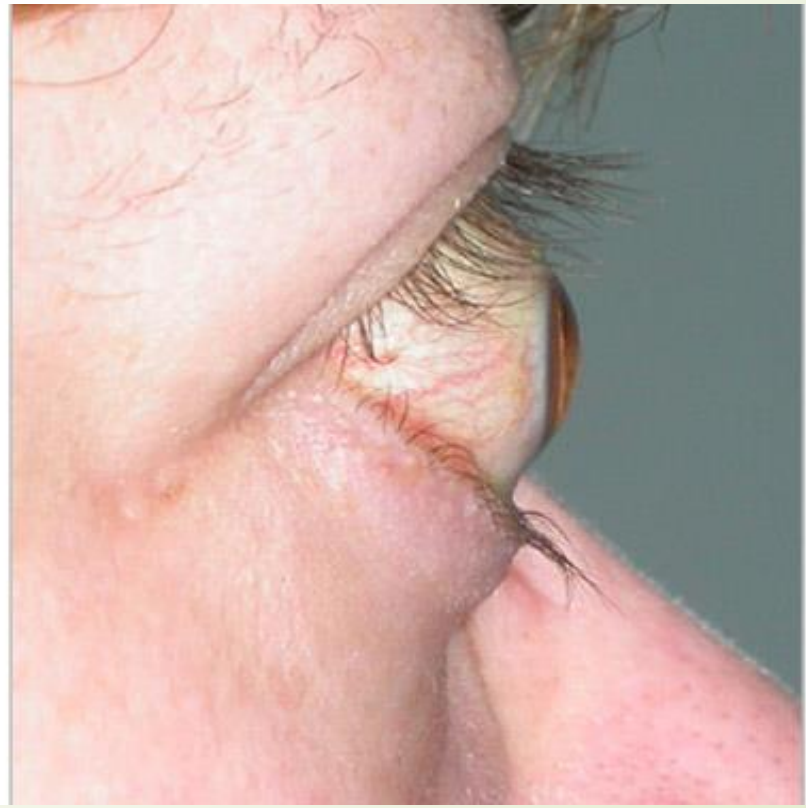
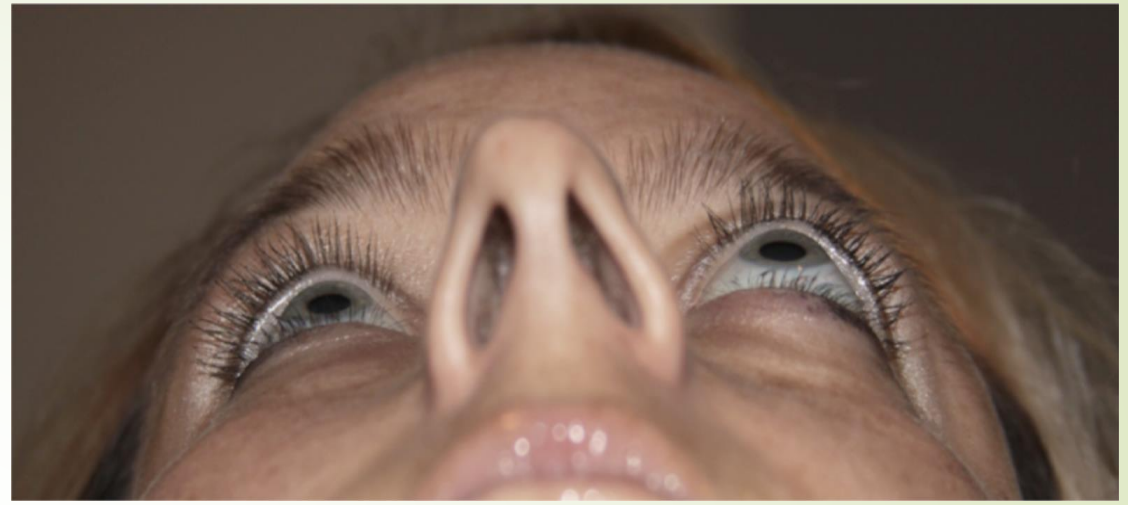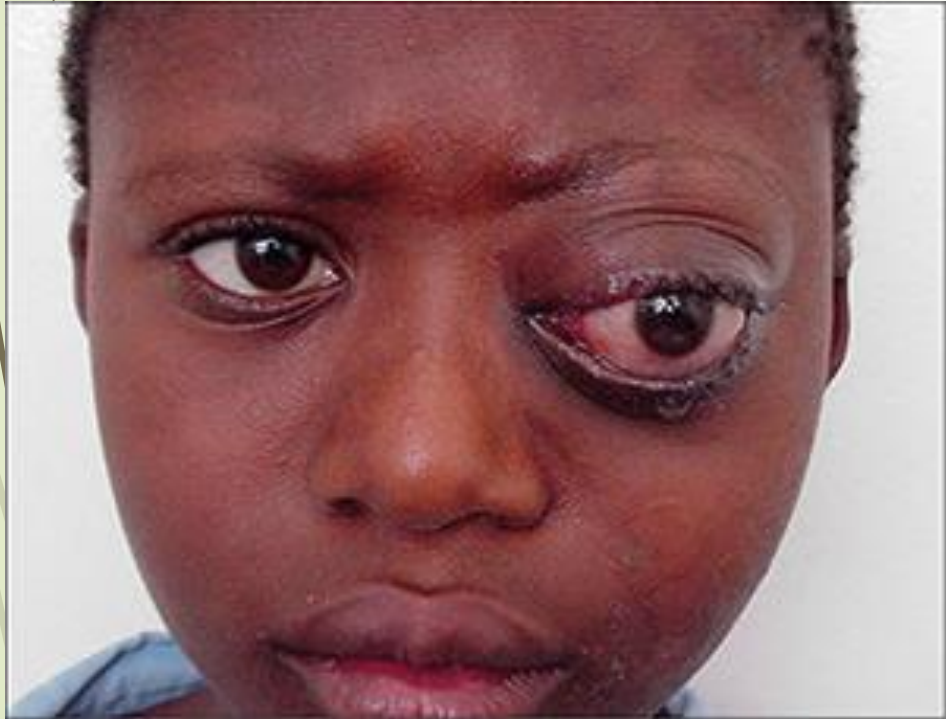Hordeolum







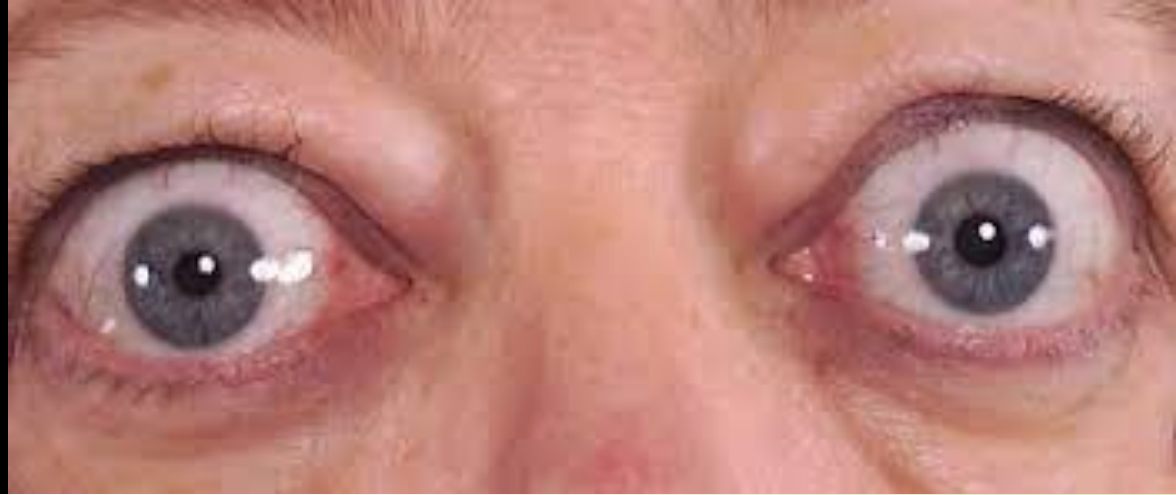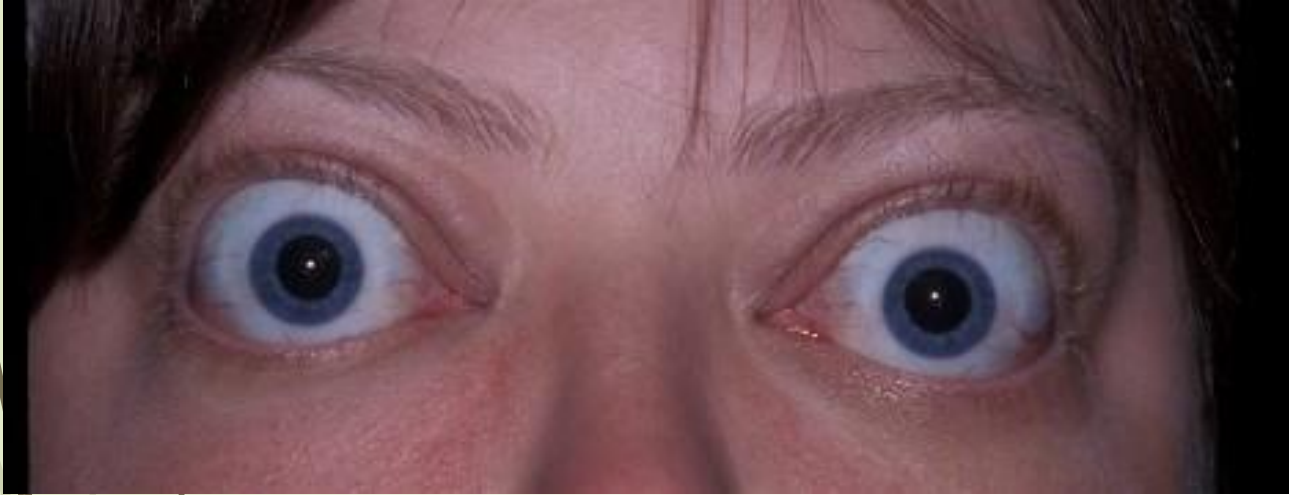proptosis



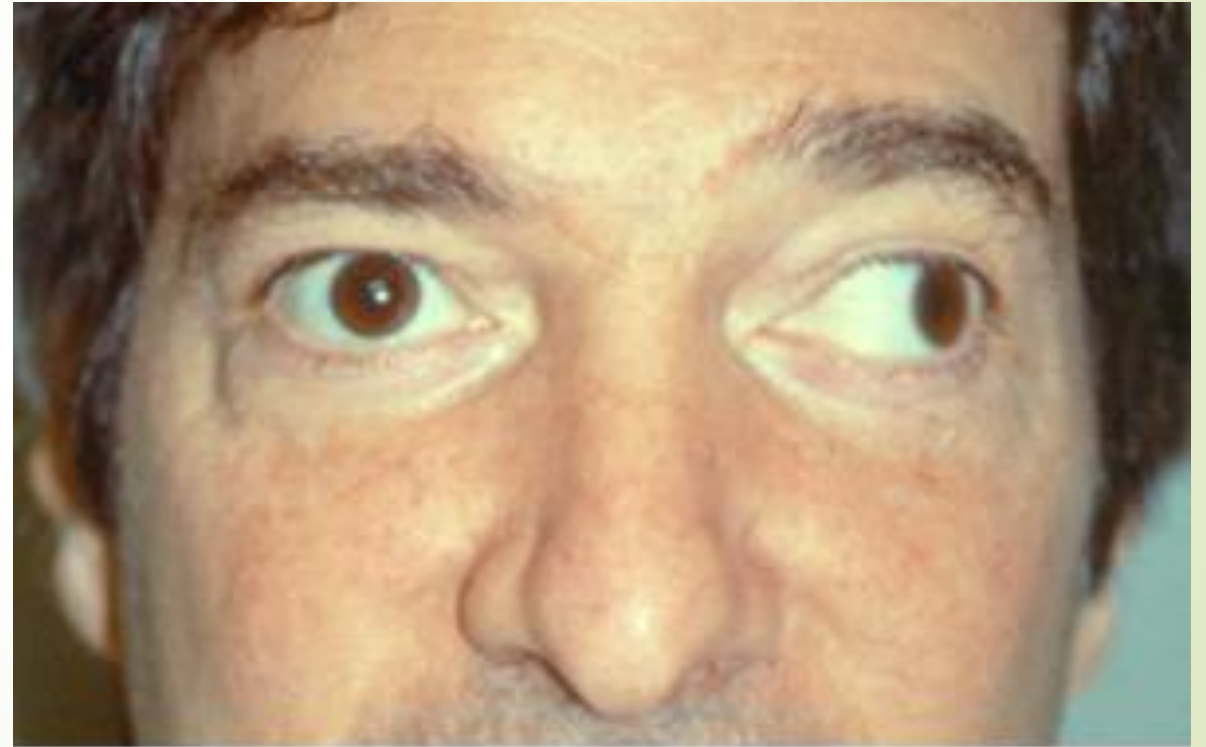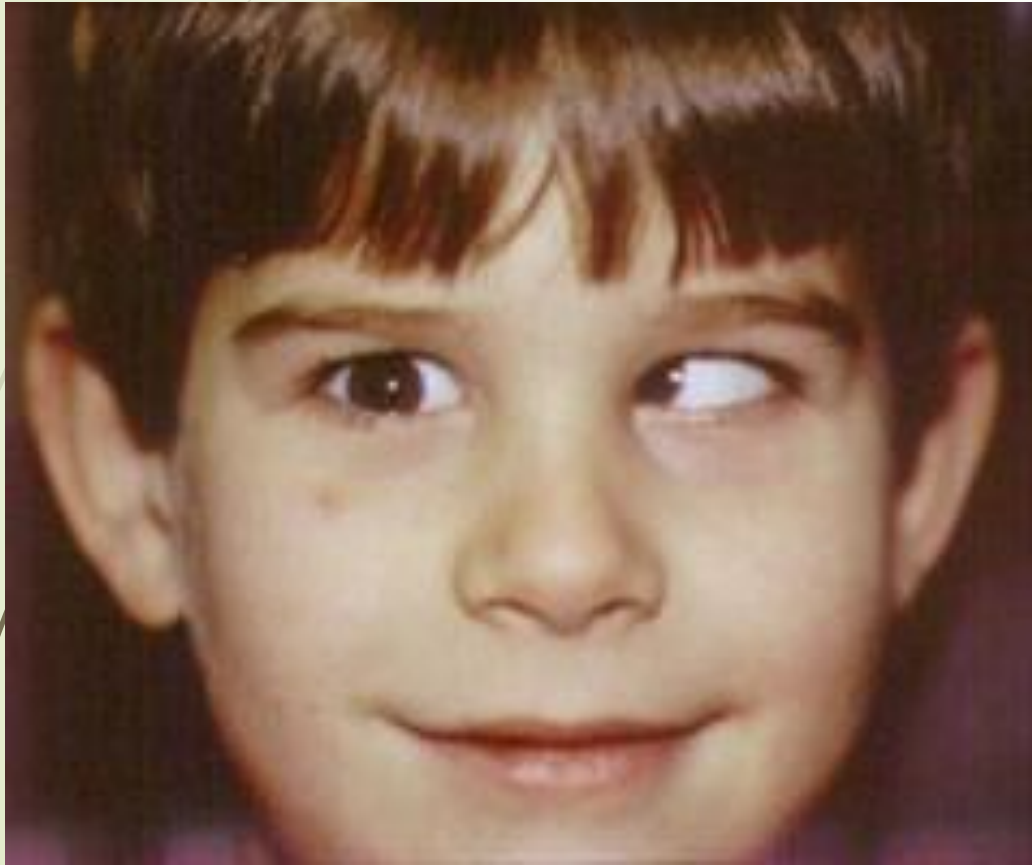Exophthalmometer



Lid Retraction



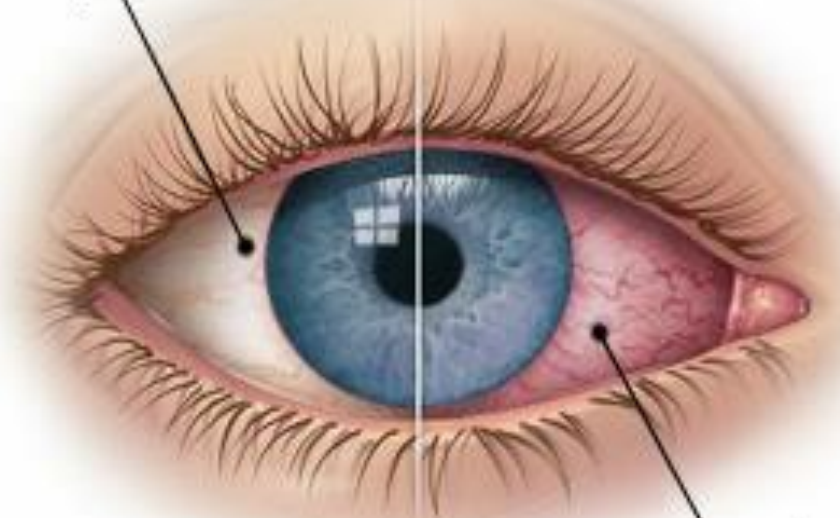Strabismus



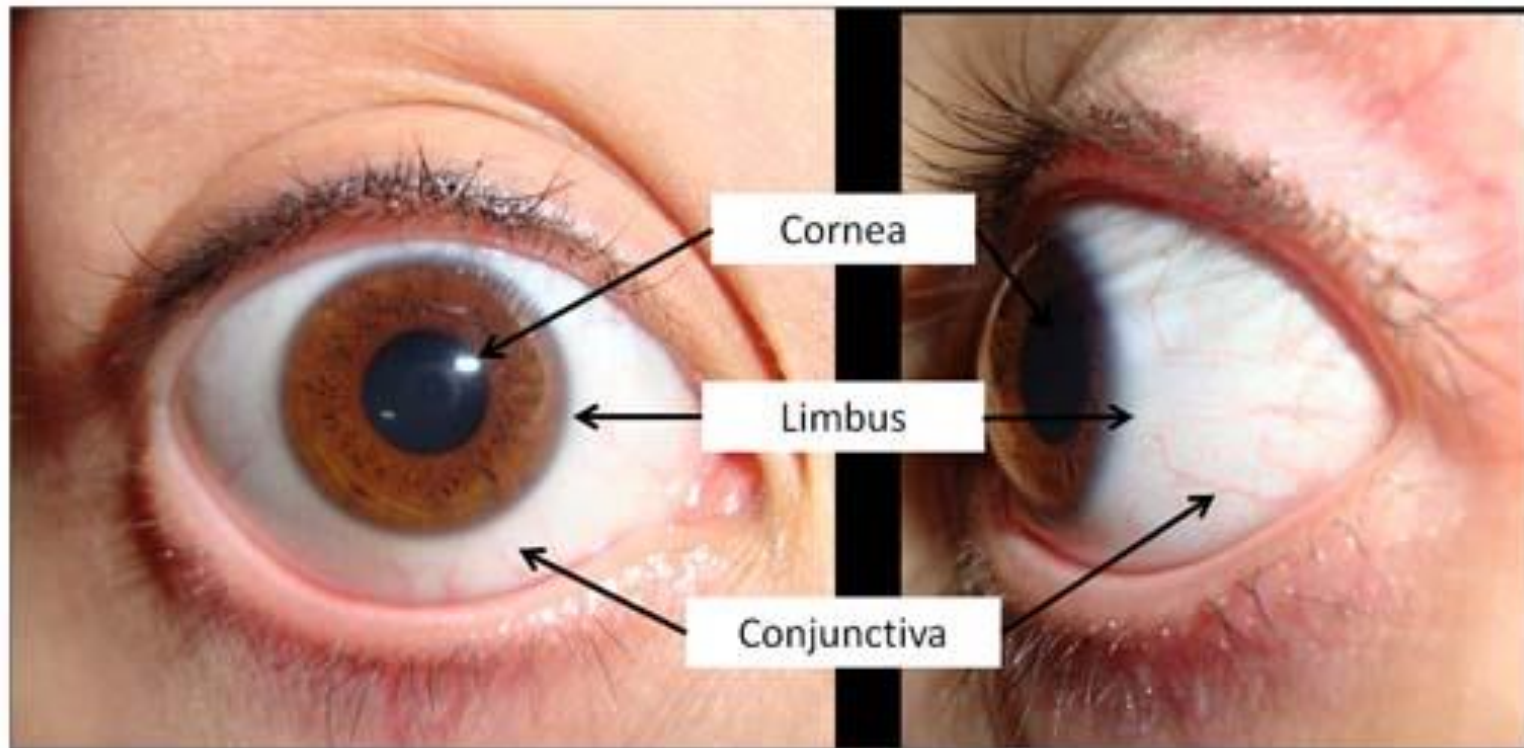
Exotropia Left



uninflamed
conjunctiva



inflamed
conjunctiva



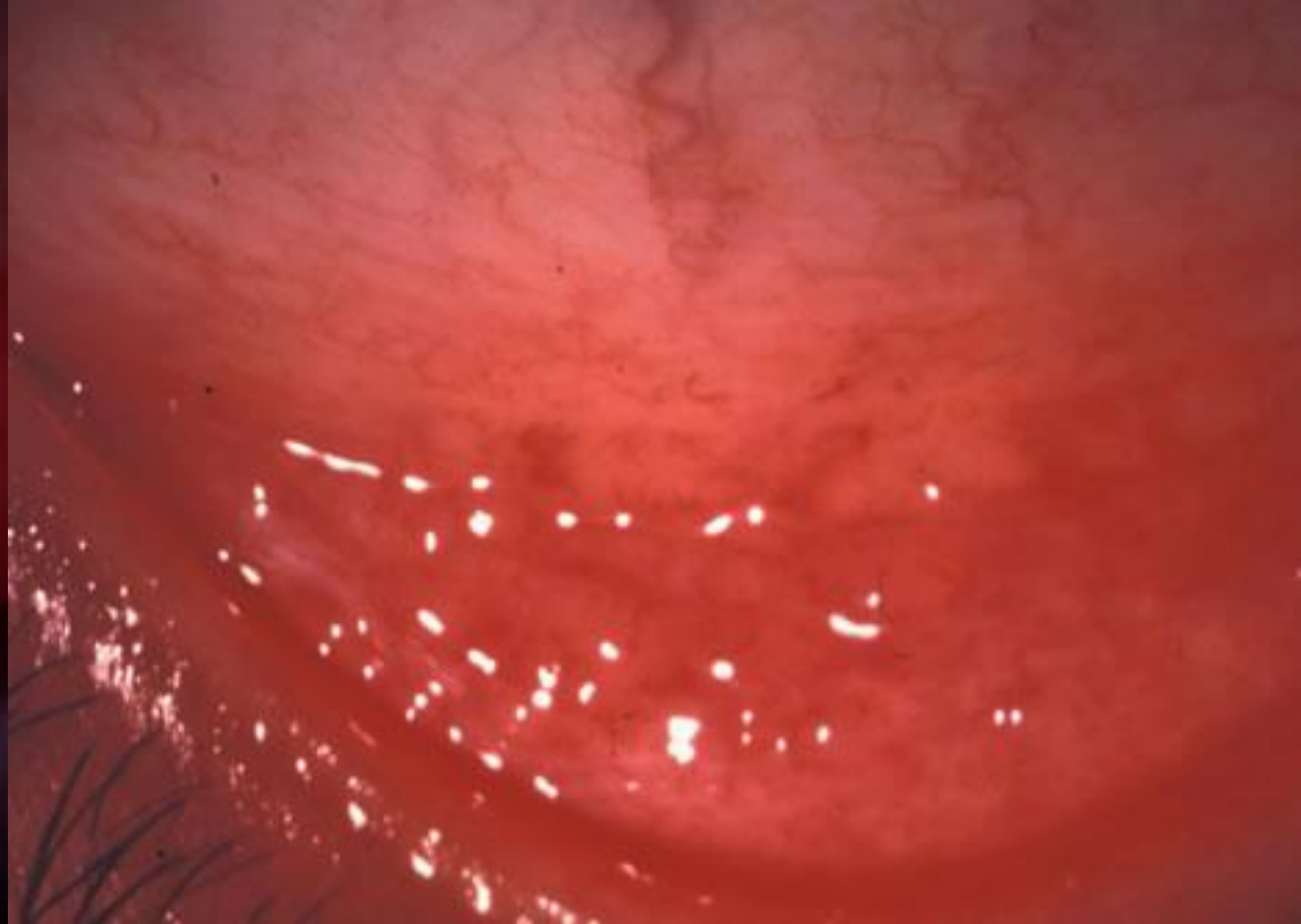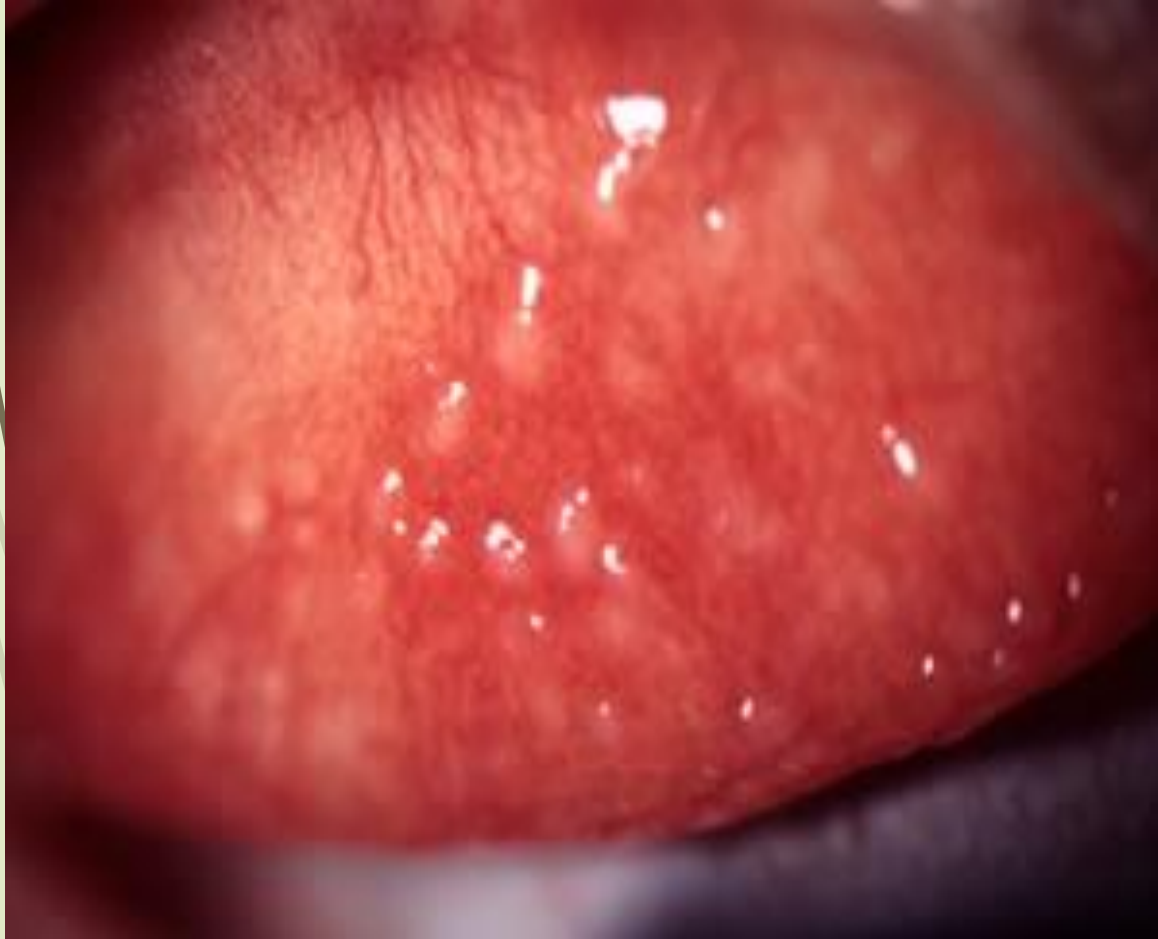
Cornea

Limbus

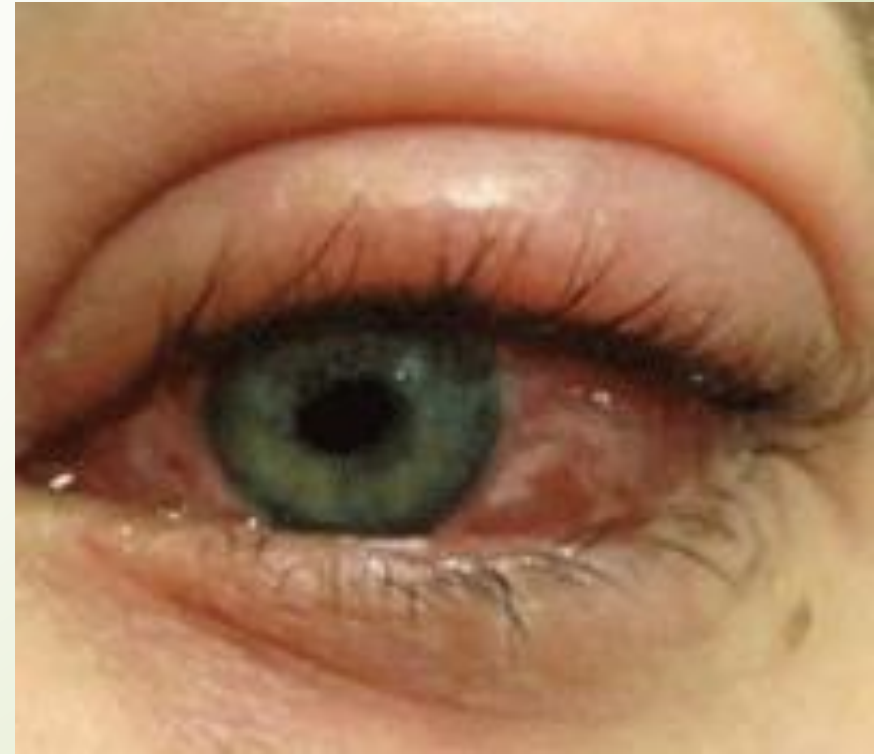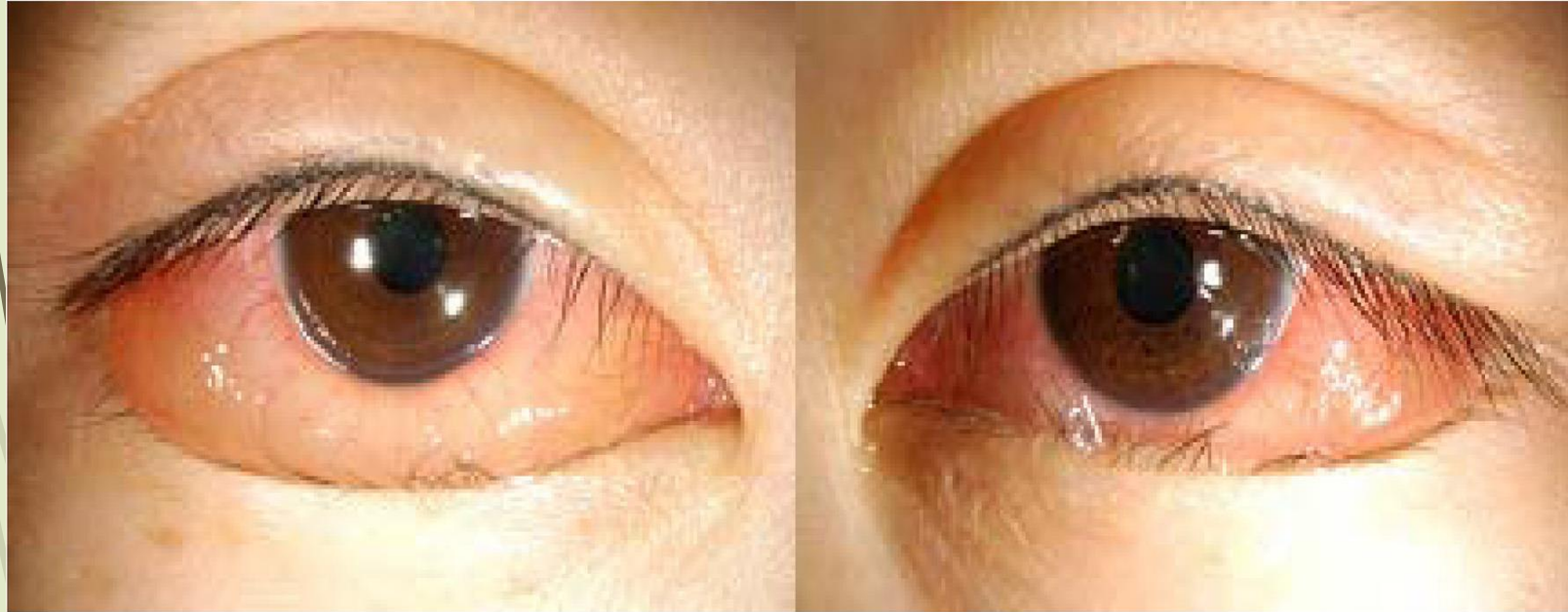Conjunctiva



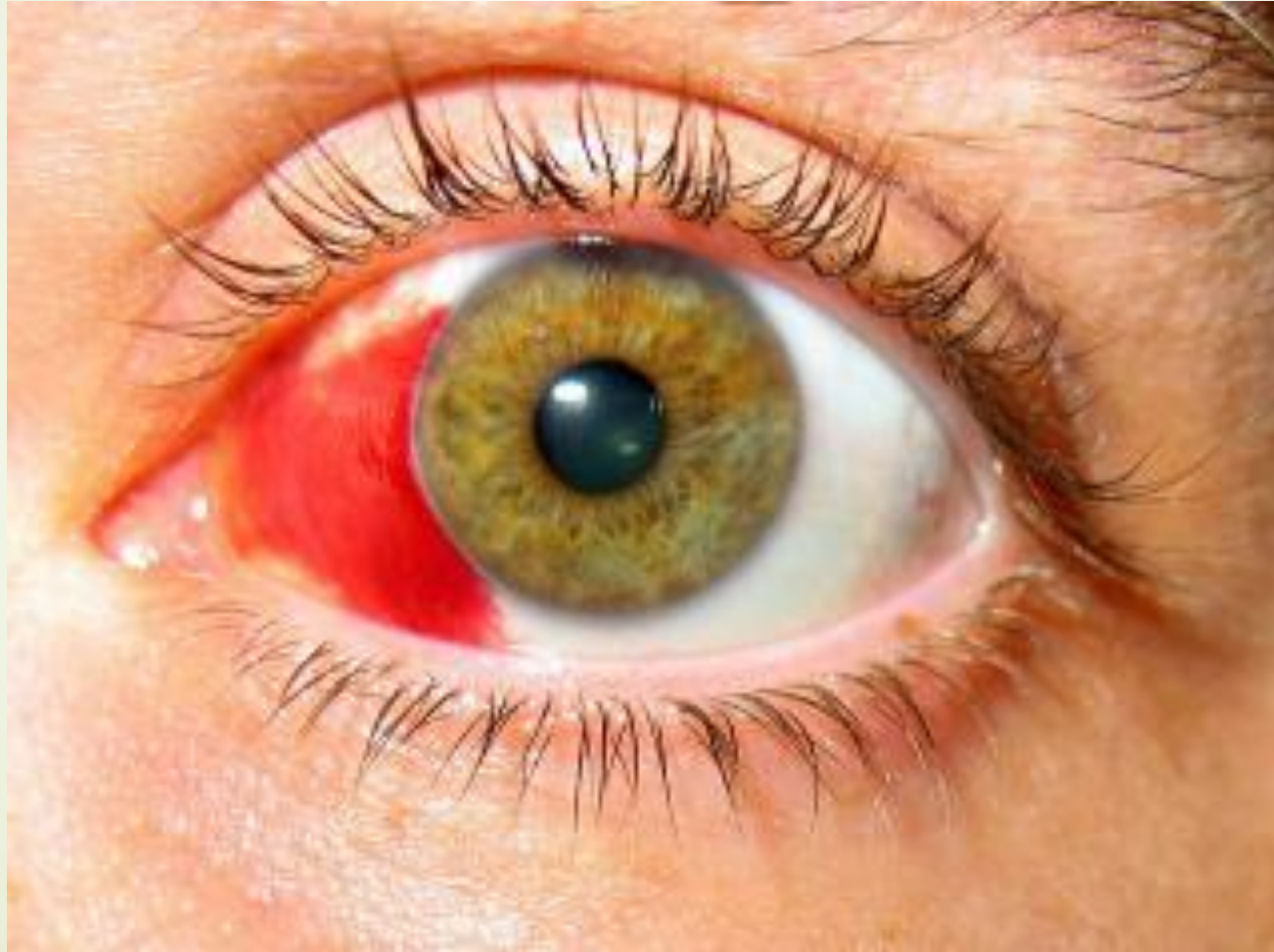Viral Conjunctivitis



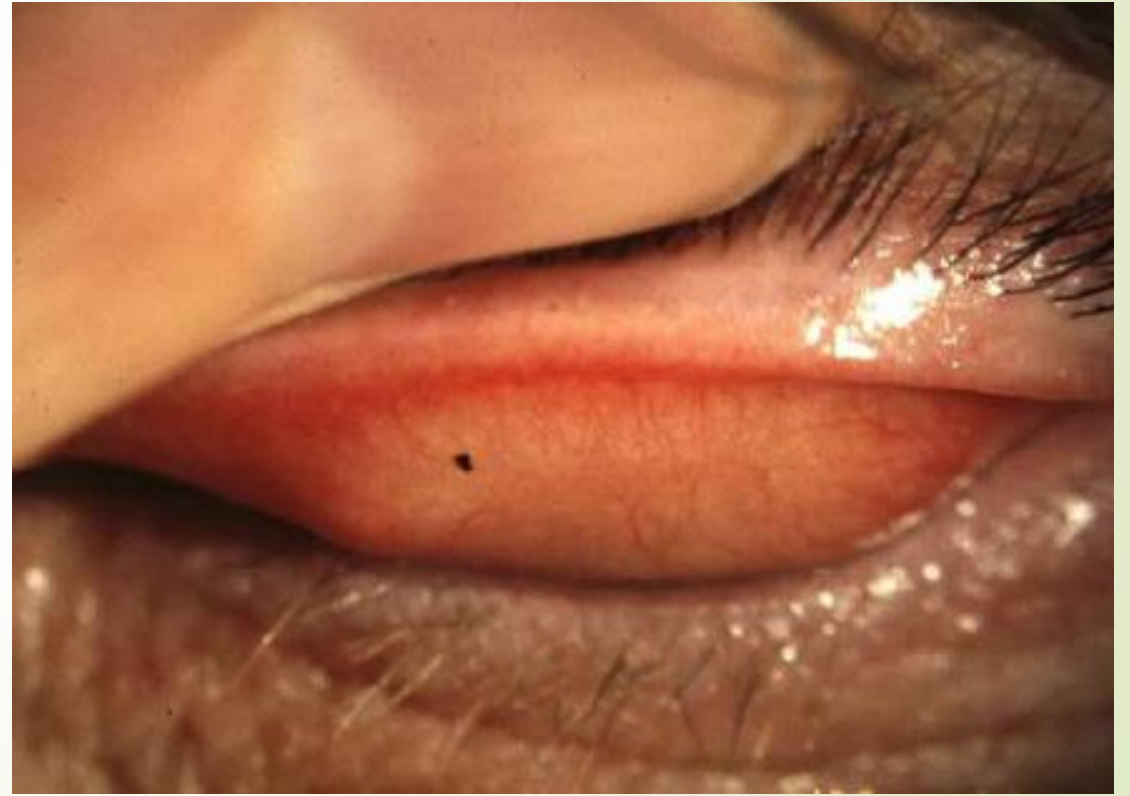
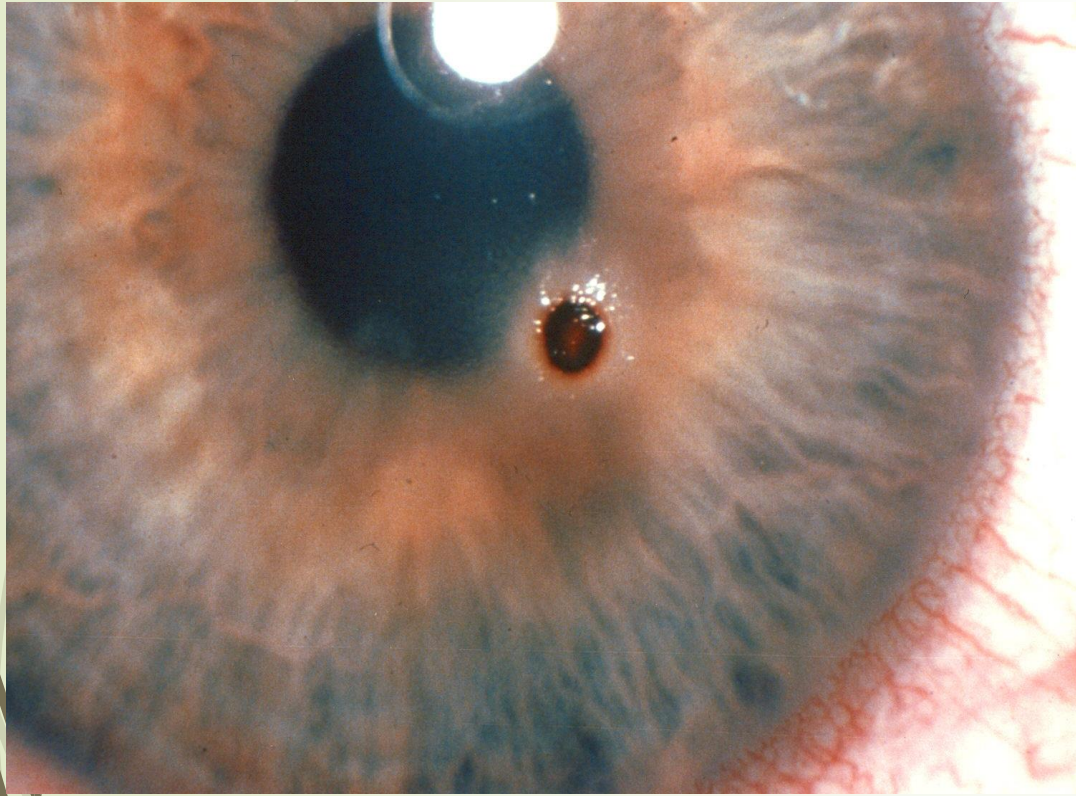
Allergic conjunctival chemosis



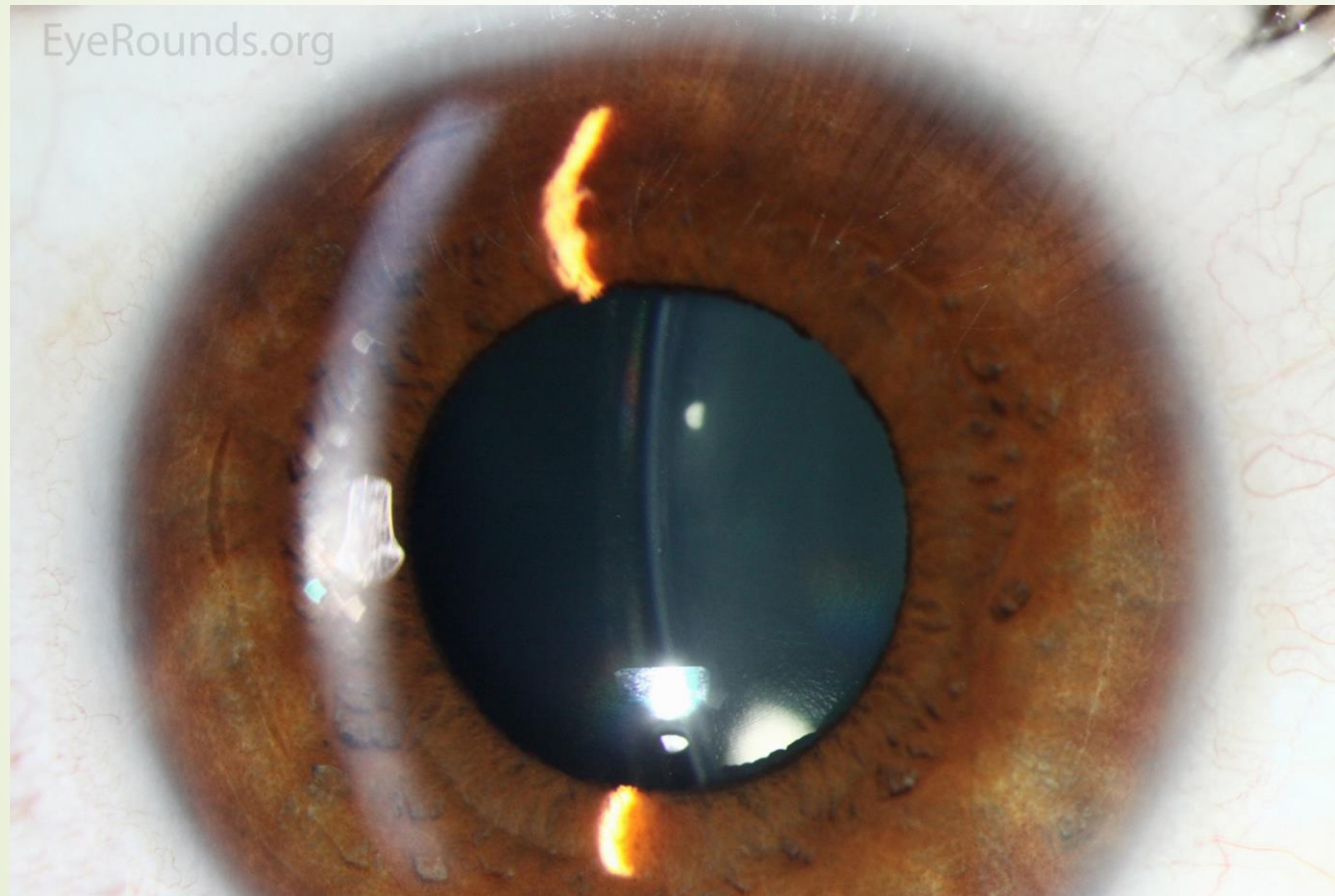
Subconjunctival hemorrhage



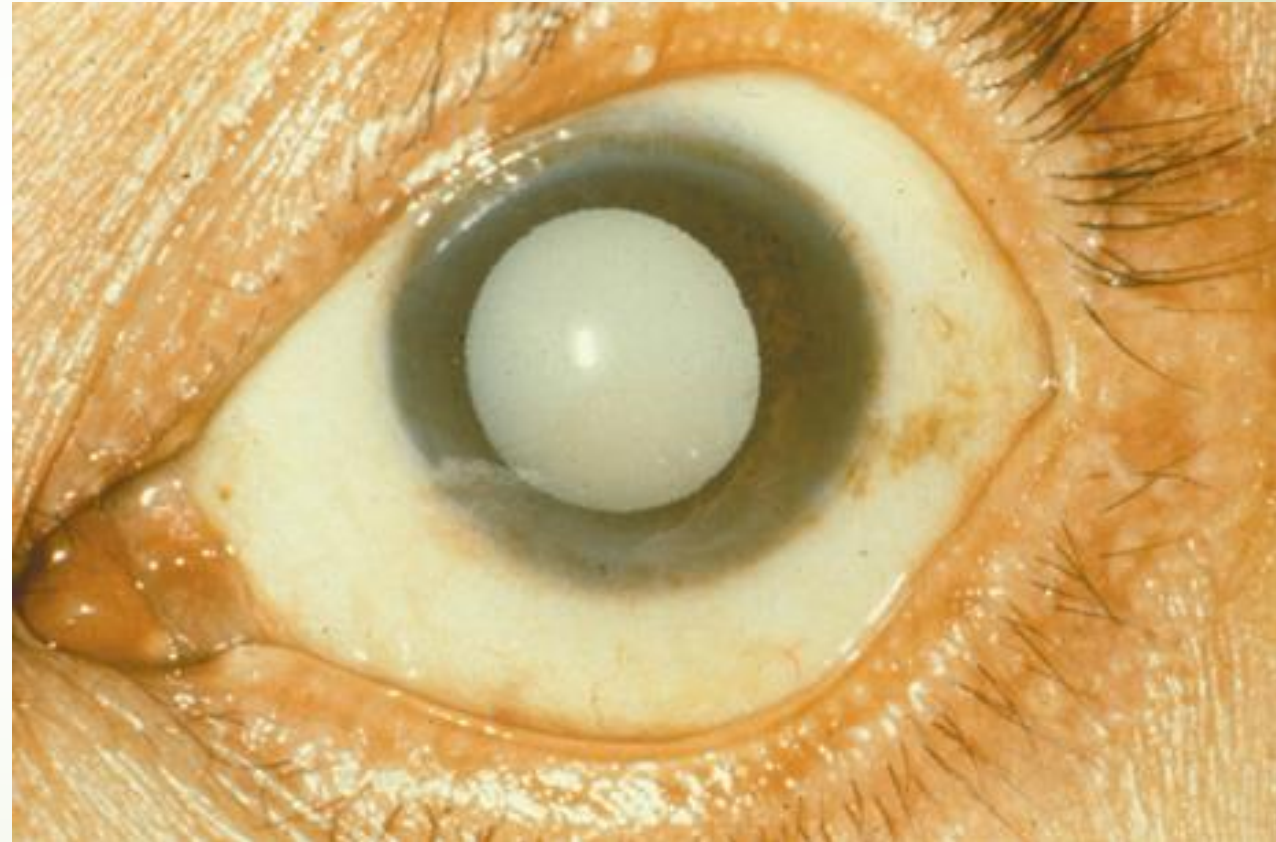
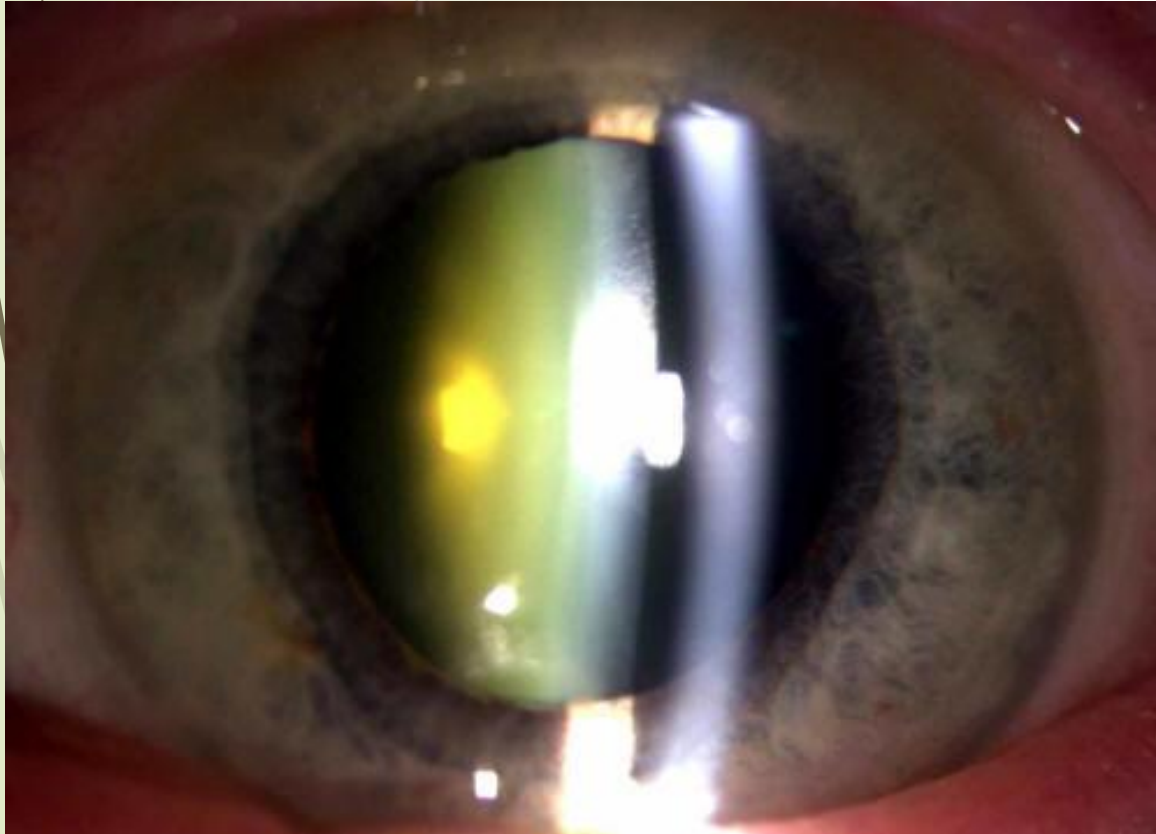
Foreign Body



Crystalline Lens



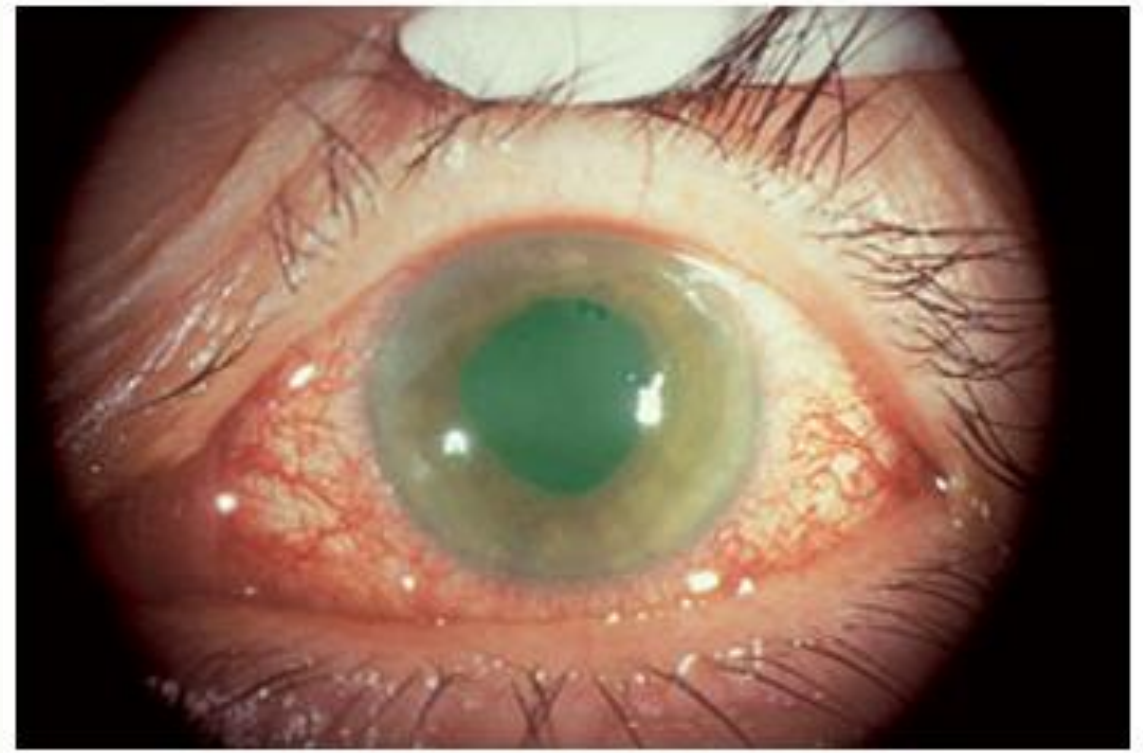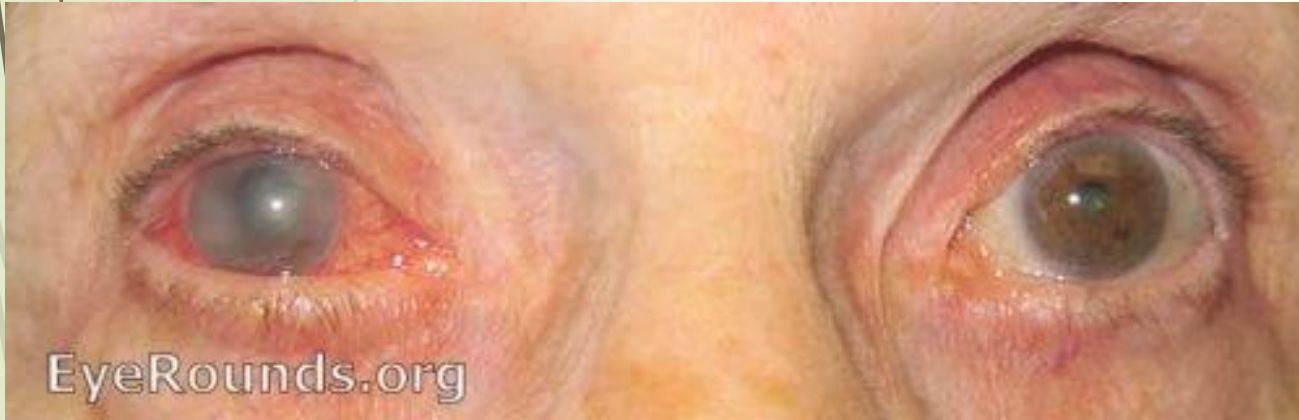Cataract



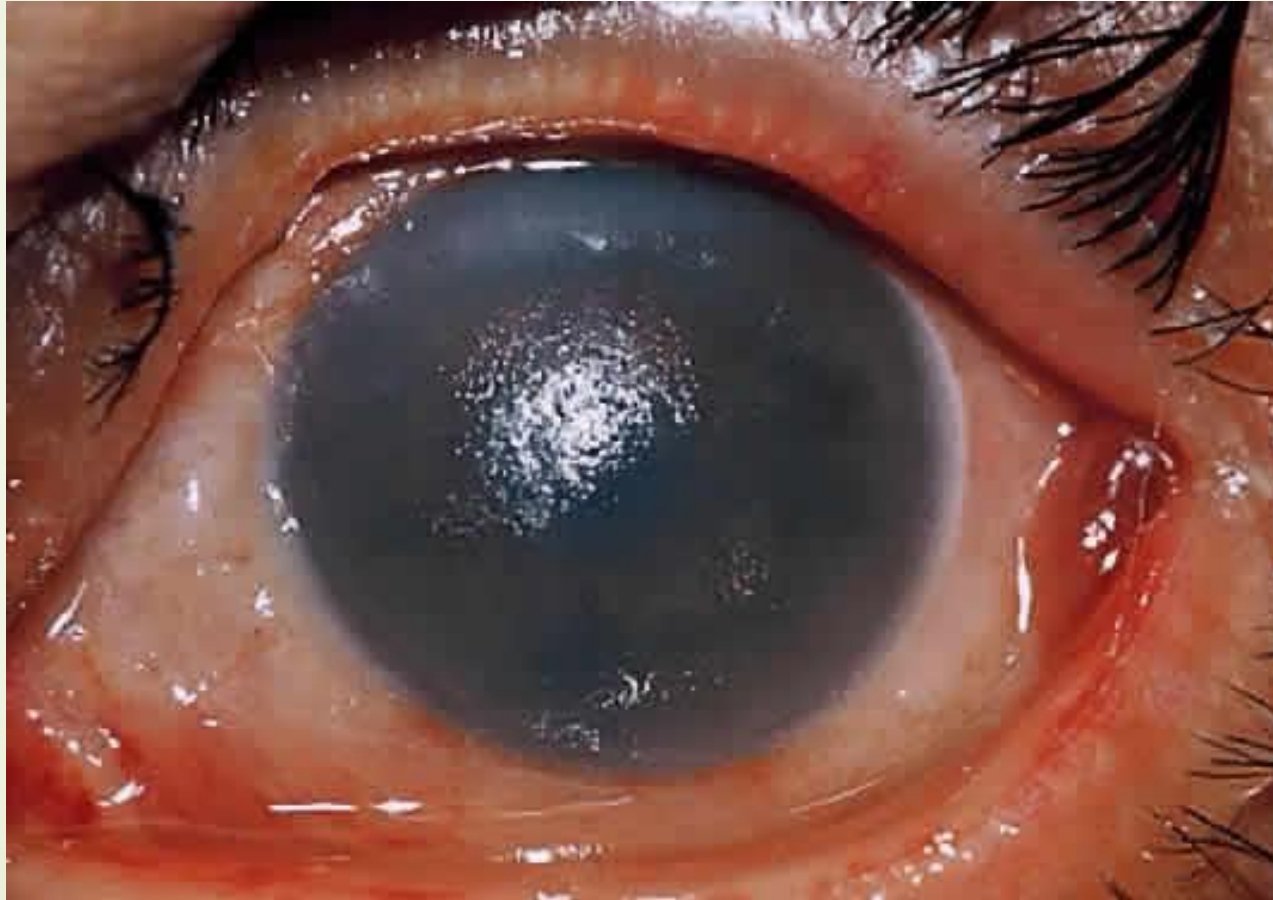


Ophthalmic Emergencies

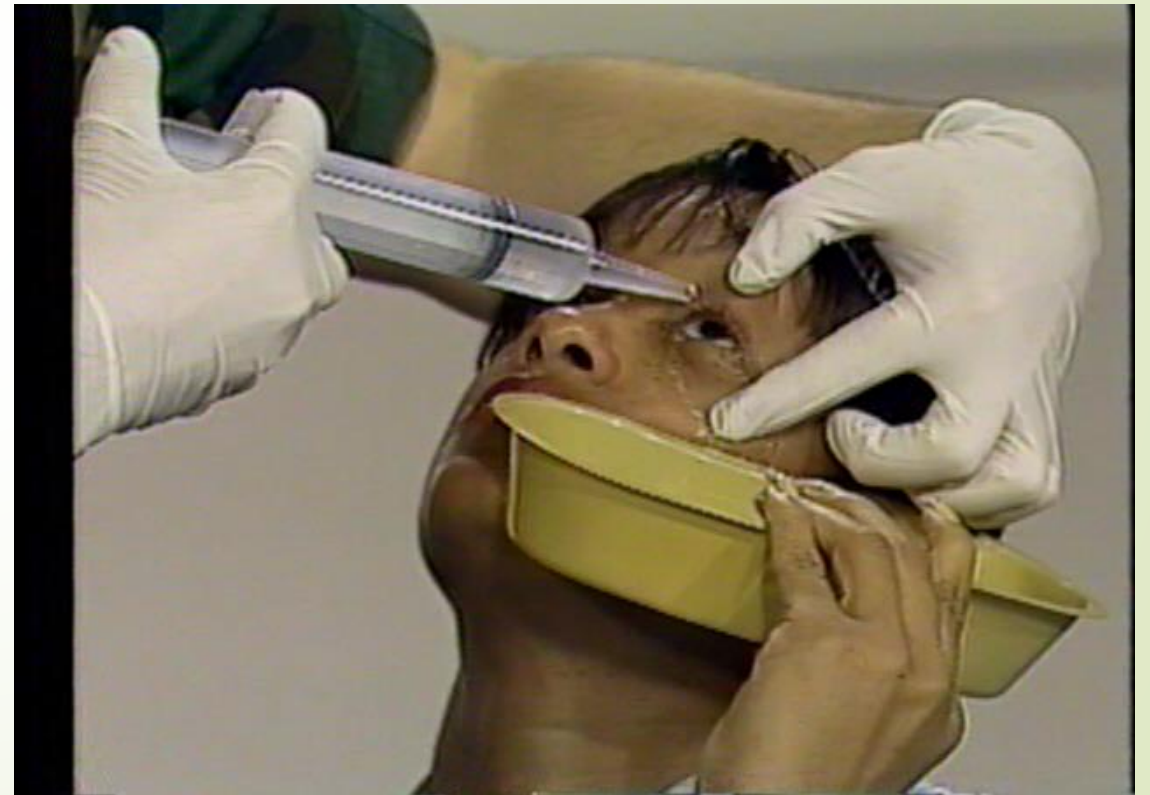Acute Angle Closure Glaucoma

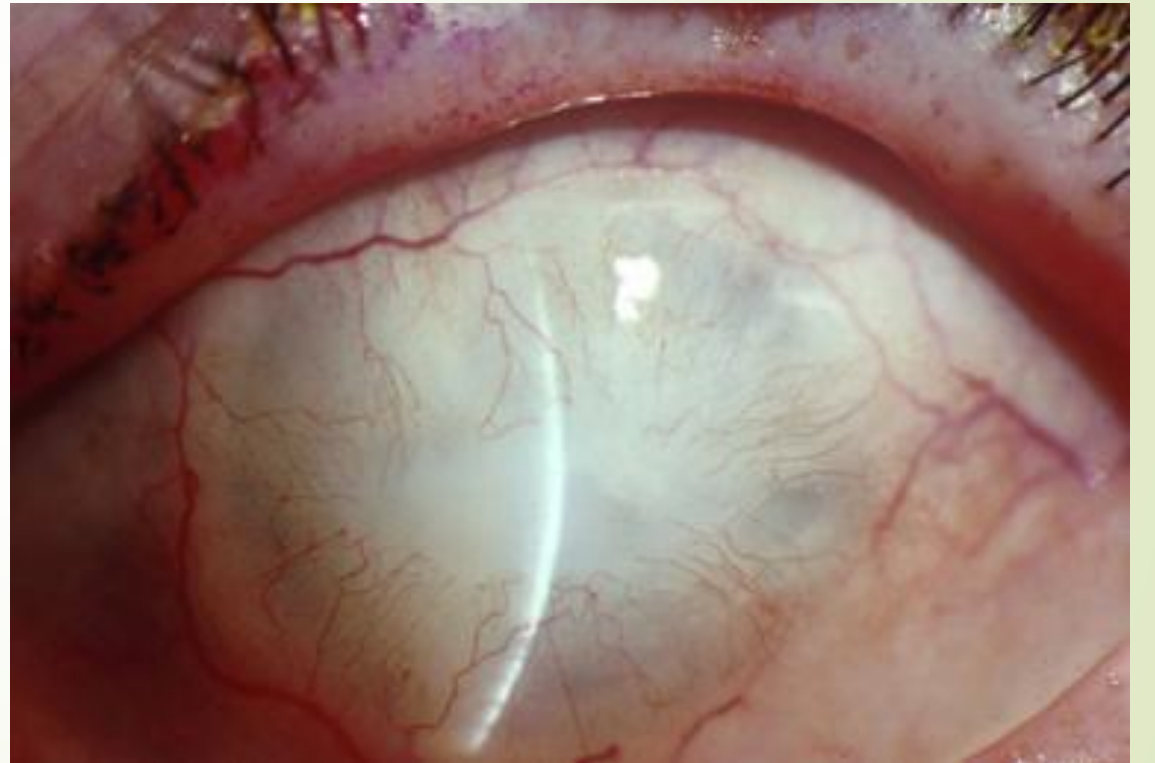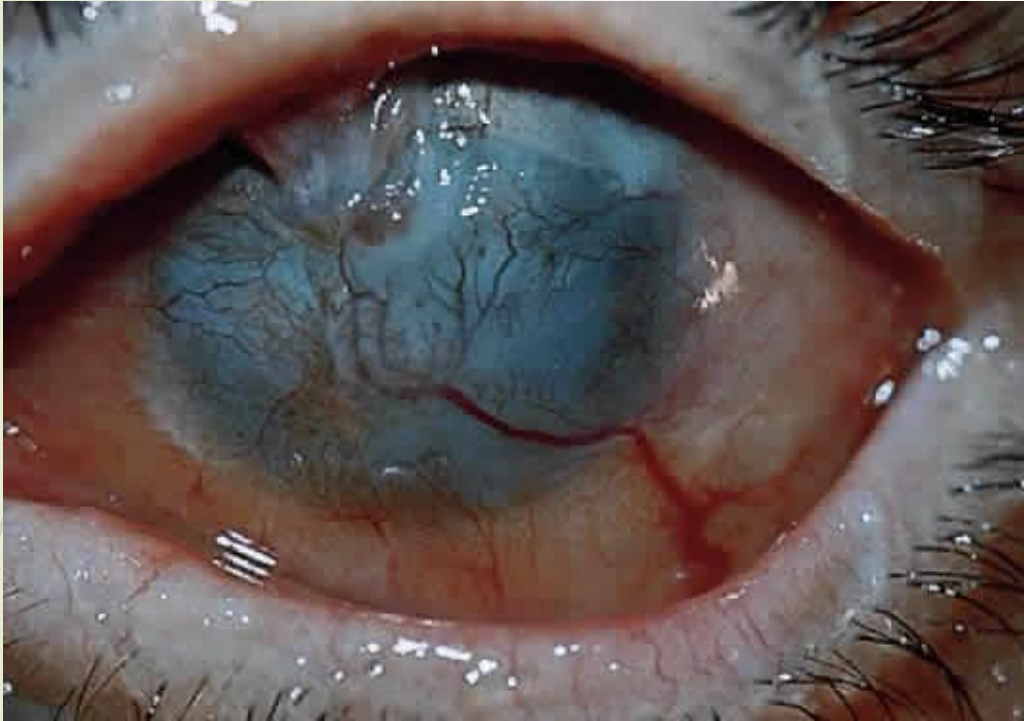


Ocular Chemical Burn

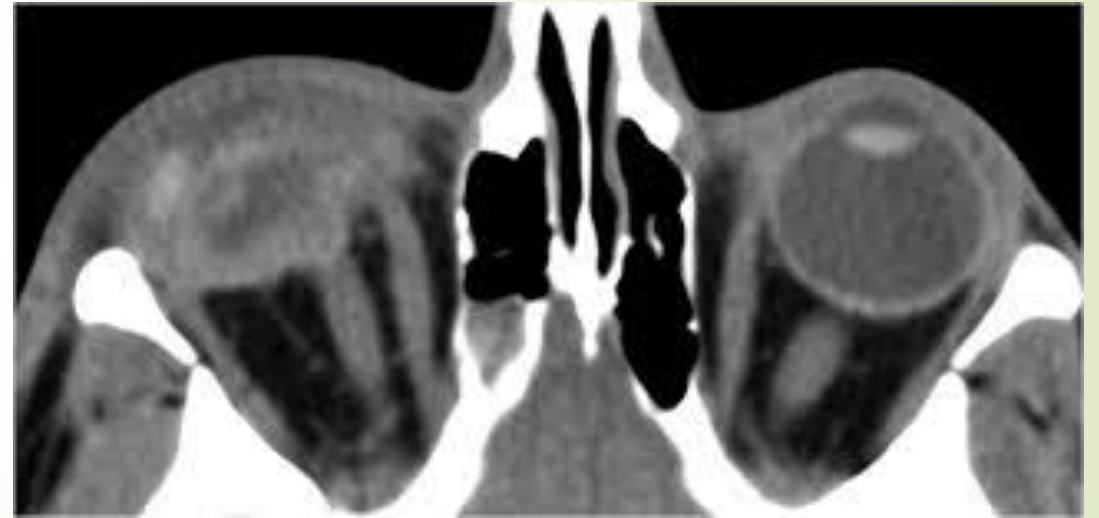
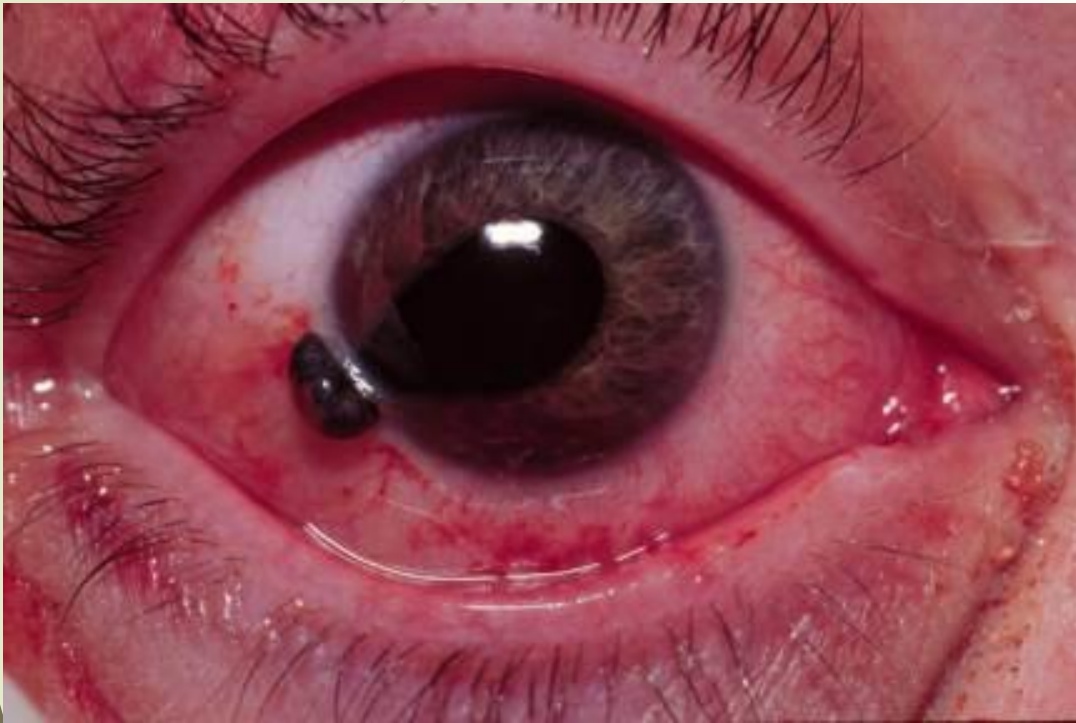

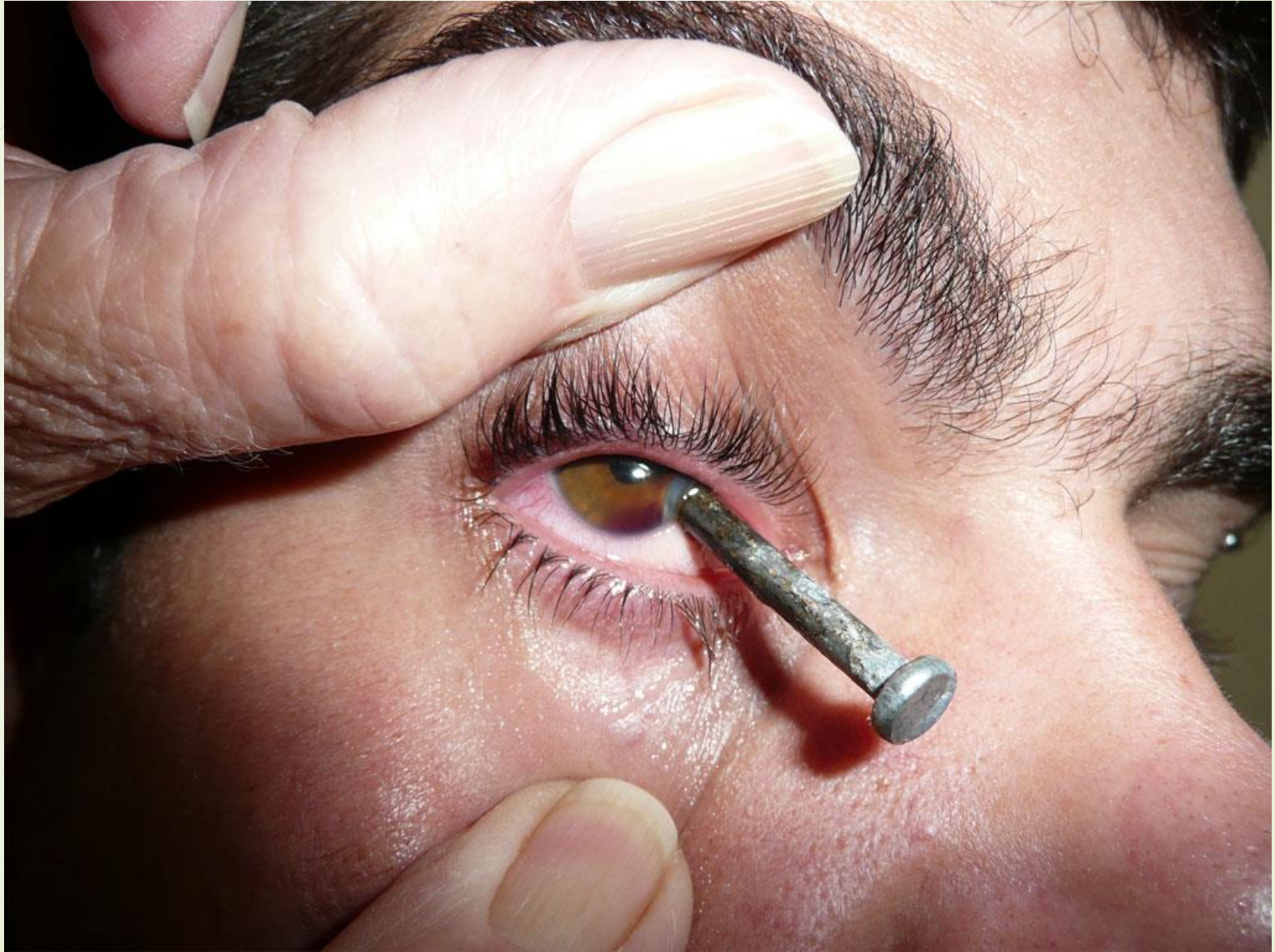Irrigation






Globe Rupture







Thank you for your
attention!